



PATIENT

Shushtrik Mukhtovova

SPECIES

Canine

BREED

Mini Schnauzer

SEX

Male Neutered

AGE

5Y

WEIGHT

17lbs

INTERPRETED BY

Sebastian Schaub, DVM
Dr. med. vet.
DipECVDI

IMAGING PERFORMED BY

Dr. Singh

HOSPITAL NAME

Animal Clinic of
Queens

REFERRING VET

Dr. Singh

INVOICE

72859

DATE

12-4-25

PRESENTING CLINICAL SIGNS

Pt has had a gagging cough for two days. Low appetite. Low energy. The mucous membrane is slightly pale.

RADIOGRAPHIC STUDY OF THE NECK, THORAX AND ABDOMEN

A complete set of radiographs including the neck, thorax and abdomen are provided for review.

RADIOGRAPHIC FINDINGS

Neck & Thorax

A positioning devise is superimposed on the most cranial aspect of the neck including the larynx. The osseous and soft tissue structures of the caudal aspects of the neck reveal no abnormalities.

The surrounding bony structures are within normal limits.

The extrathoracic soft tissues present homogeneous without abnormalities.

The heart is of normal size and shape; there is no evidence of cardiac chamber or vascular enlargement. The pulmonary vasculature is within normal limits.

The cranial mediastinum presents the expected soft tissue opacity. The mediastinal width is less than twice the width of the vertebral column at the same level.

The trachea is normal in diameter and presents the anticipated course. The luminal outline of the trachea is smooth.

The bronchial tree presents with thin walls and tapers uniformly towards the periphery as expected.

The lung parenchyma presents the expected architecture and opacity; the intrapulmonary vascular branching is seen up to the third order lung vessels.

The diaphragm is well delineated with even surface and the expected mild cranial bulging of the diaphragmatic cupola.

Abdomen

The surrounding bony structures are within normal limits.

No abnormalities of the extraabdominal soft tissues are noted. The abdominal wall is smooth and thin.

The serosal detail is maintained throughout the peritoneal and retroperitoneal space.

The liver is appropriate in position, size and presents uniform opacity.

The splenic head is in the anticipated position and within normal limits for size and opacity. The splenic body and tail are considered normal for position, size, shape and opacity.

Both kidneys are seen and present with normal size, shape, delineation and opacity. The urinary bladder is in its anticipated position. No radiopaque calculi are noted throughout the upper and lower urinary tract.

The stomach is in its anticipated position and presents normal content.

The small intestinal loops are of even diameter and non-dilated, a small amount of gas is seen within the small intestinal loops and considered within normal limits.



PATIENT

Shushtrik Mukhtovova

SPECIES

Canine

BREED

Mini Schnauzer

SEX

Male Neutered

AGE

5Y

WEIGHT

17lbs

INTERPRETED BY

Sebastian Schaub, DVM
Dr. med. vet.
DipECVDI

IMAGING PERFORMED BY

Dr. Singh

HOSPITAL NAME

Animal Clinic of
Queens

REFERRING VET

Dr. Singh

INVOICE

72859

DATE

12-4-25

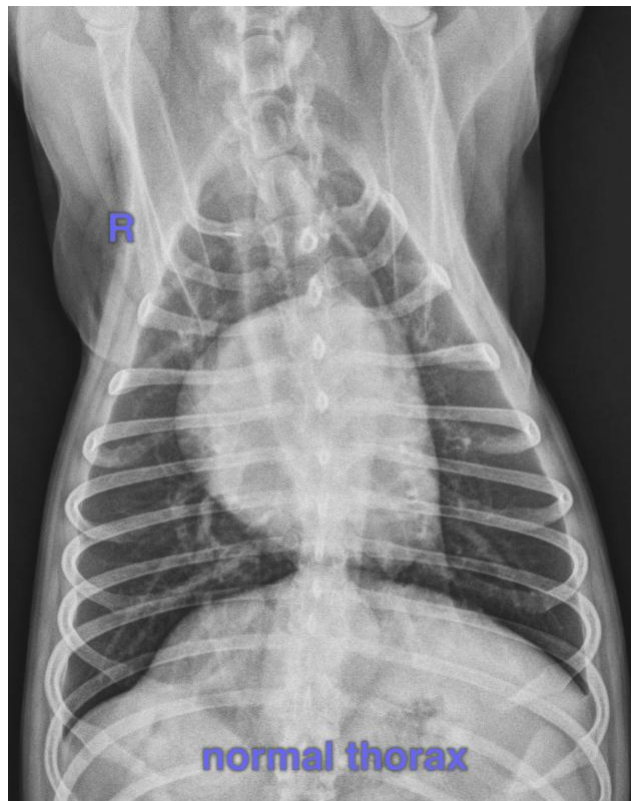
The colon is seen in the expected position and presents with appropriate content.

RADIOGRAPHIC DIAGNOSIS

- Normal neck
- Normal thorax
- Normal abdomen

INTERPRETATION OF THE FINDINGS & FURTHER RECOMMENDATIONS

The radiographic study reveals no abnormalities and an underlying cause for the cough cannot be specified. However, a negative radiographic study does not rule out possible underlying tracheitis/bronchitis.



The information and recommendations provided are based on the images presented by the referring veterinarian/sonographer. No evaluation can be communicated regarding pathology that was not visible in the image/video clips provided.

Thank you for this referral. If the clinical or image interpretation does not parallel your findings or if I can be of any further assistance please contact me.

Sebastian Schaub, Sebastian Schaub, DVM, Dr. med. vet. DipECVDI
info@sonopath.com