



PATIENT

Akira Otero

SPECIES

Canine

BREED

Golden Retriever

SEX

Female Spayed

AGE

8.5Y

WEIGHT

62lbs

INTERPRETED BY

Sebastian Schaub, DVM
Dr. med. vet.
DipECVDI

IMAGING PERFORMED BY

Dr. Abina Glennon

HOSPITAL NAME

New Bridge Veterinary
Practice

REFERRING VET

Dr. Abina Glennon

INVOICE

73165

DATE

12-31-25

PRESENTING CLINICAL SIGNS

Limping right thoracic limb

RADIOGRAPHIC STUDY OF THE ANTEBRACHIUM

Radiographs of the right antebrachium in two orthogonal image planes and a craniocaudal view of the left antebrachium are provided for review.

RADIOGRAPHIC FINDINGS

Along the cranial cortex of the proximal half of the diaphysis of the right ulna, solid but irregular margined new bone formation is seen – partially obliterating the interosseous space. The caudal cortex of the right radius, opposing the new bone formation of the ulnar is irregular.

In the craniocaudal view of the left antebrachium, at the proximal segment of the left ulna, solid and smooth new bone formation is seen.

RADIOGRAPHIC DIAGNOSIS

- Benign solid new bone formation accentuated along the cranial cortex of the right ulna and osseous remodeling caudal cortex right radius
- Smooth solid new bone formation cranial cortex left ulna

INTERPRETATION OF THE FINDINGS & FURTHER RECOMMENDATIONS

The new bone formation is appreciated predominantly along the region of the insertion of the interosseous ligament and the presumptive diagnosis chronic desmitis and enthesiophytosis of the radio-ulnar interosseous ligament, R>>>L. Recommend discussing possible conservative or surgical management options with an orthopedic surgeon.



PATIENT

Akira Otero

SPECIES

Canine

BREED

Golden Retriever

SEX

Female Spayed

AGE

8.5Y

WEIGHT

62lbs

INTERPRETED BY

Sebastian Schaub, DVM
Dr. med. vet.
DipECVDI

IMAGING PERFORMED BY

Dr. Abina Glennon

HOSPITAL NAME

New Bridge Veterinary
Practice

REFERRING VET

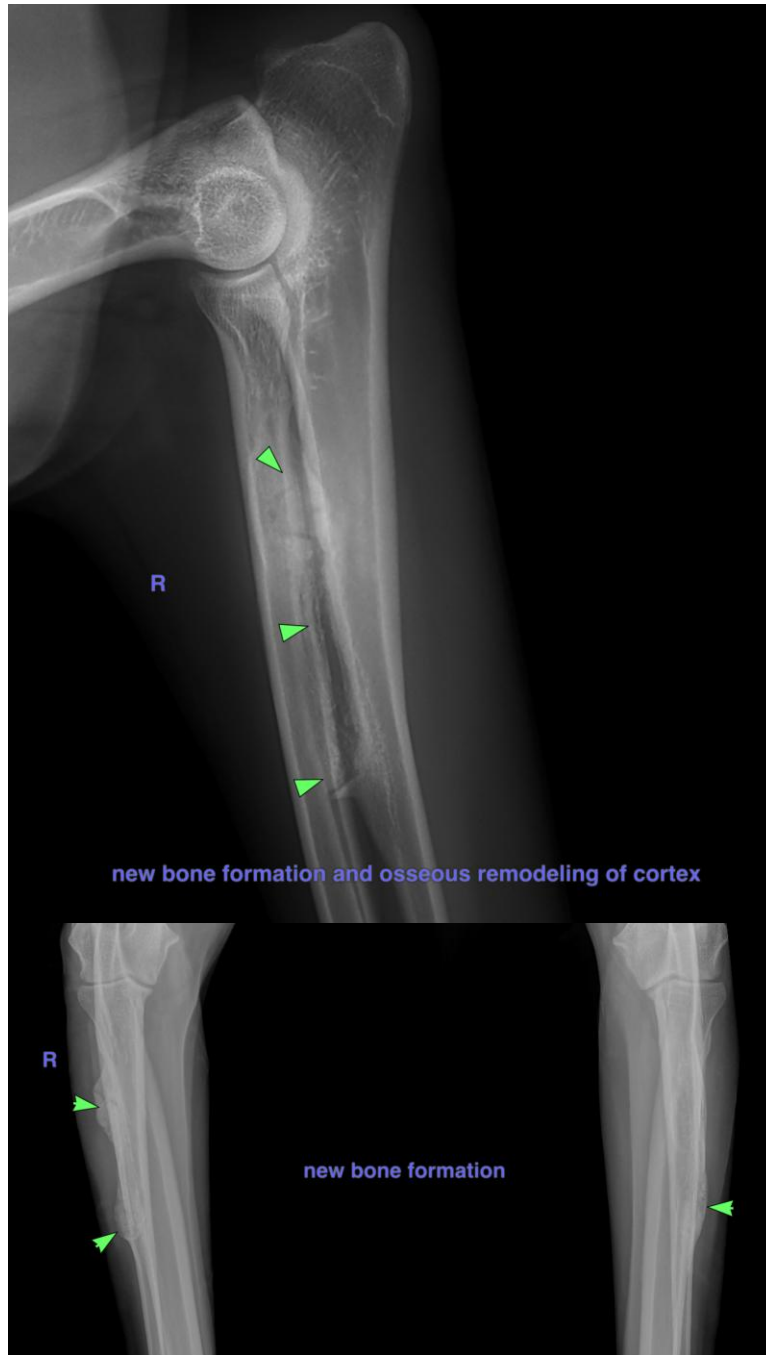
Dr. Abina Glennon

INVOICE

73165

DATE

12-31-25





PATIENT

Akira Otero

SPECIES

Canine

BREED

Golden Retriever

SEX

Female Spayed

AGE

8.5Y

WEIGHT

62lbs

INTERPRETED BY

Sebastian Schaub, DVM
Dr. med. vet.
DipECVDI

IMAGING PERFORMED BY

Dr. Abina Glennon

HOSPITAL NAME

New Bridge Veterinary
Practice

REFERRING VET

Dr. Abina Glennon

INVOICE

73165

DATE

12-31-25

The information and recommendations provided are based on the images presented by the referring veterinarian/sonographer. No evaluation can be communicated regarding pathology that was not visible in the image/video clips provided.

Thank you for this referral. If the clinical or image interpretation does not parallel your findings or if I can be of any further assistance please contact me.

Sebastian Schaub, Sebastian Schaub, DVM, Dr. med. vet. DipECVDI
info@sonopath.com