

**PATIENT**

Rogers Kirkpatrick

**PRESENTING CLINICAL SIGNS**

O noticed Rogers gasping for air sometimes. Otherwise healthy and no open mouth breathing  
Abnormal PE/Chem/CBC/UA Results: No crackles or wheezes, no murmur during the physical exam.

**SPECIES**

Feline

**RADIOGRAPHIC STUDY OF THE THORAX**

Radiographs of the thorax in three imaging planes are provided for review.

**BREED**

Domestic Shorthair

**RADIOGRAPHIC FINDINGS**

The surrounding bony structures are within normal limits.

The extrathoracic soft tissues present homogeneous without abnormalities.

**SEX**

Male Neutered

The pericardial sac is accentuated by fat. The pulmonary vasculature is within normal limits.

The trachea is normal in diameter and presents the anticipated course. The luminal outline of the trachea is smooth.

**AGE**

4

Mild increased visibility of the bronchial walls is present.

The lung parenchyma presents the expected architecture and opacity; the intrapulmonary vascular branching is seen up to the third order lung vessels.

**INTERPRETED BY**

Sebastian Schaub, DVM  
Dr. med. vet. DipECVDI

The diaphragm is well delineated with even surface and the expected mild cranial bulging of the diaphragmatic cupola.

**HOSPITAL NAME**

Truscott Animal  
Hospital

**RADIOGRAPHIC DIAGNOSIS**

- Mild bronchial pattern
- No evidence of air-trapping

**REFERRING VET**

Erini Abraham

**INTERPRETATION OF THE FINDINGS & FURTHER RECOMMENDATIONS**

The mild bronchial pattern is supporting the diagnosis of mild feline bronchial disease without evidence of air-trapping. Either monitoring the patient if clinical signs deteriorate or starting inhalation therapy with an asthma inhaler appear as feasible options.

**INVOICE**

49336

**DATE**

12-31-21



**PATIENT**

Rogers Kirkpatrick

**SPECIES**

Feline

**BREED**

Domestic Shorthair

**SEX**

Male Neutered

**AGE**

4

**INTERPRETED BY**

Sebastian Schaub, DVM  
Dr. med. vet. DipECVDI

**HOSPITAL NAME**

Truscott Animal  
Hospital

**REFERRING VET**

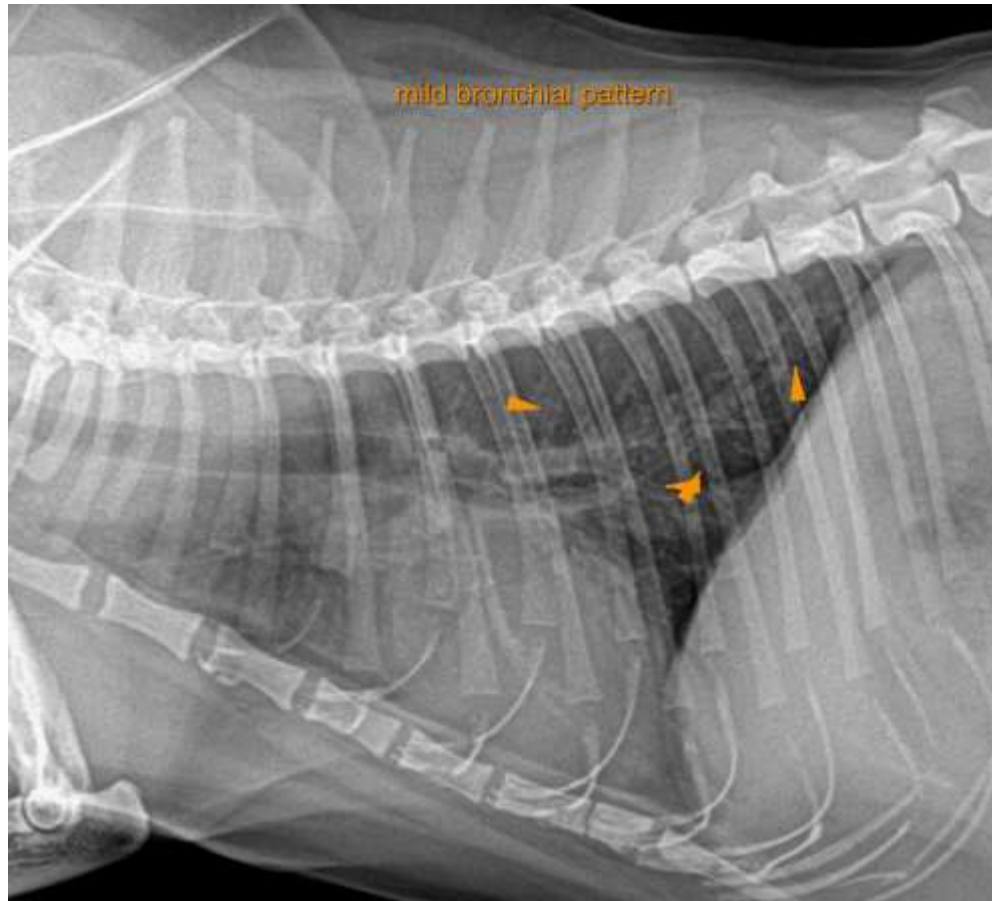
Erini Abraham

**INVOICE**

49336

**DATE**

12-31-21



The information and recommendations provided are based on the images presented by the referring veterinarian. No evaluation can be communicated regarding pathology that was not visible in the image/video clips provided.

Thank you for this referral. If the clinical or image interpretation does not parallel your findings or if I can be of any further assistance please contact me.

**Sebastian Schaub**, Sebastian Schaub, DVM, Dr. med. vet. DipECVDI  
sebast.schaub@gmail.com