



PATIENT

Cyrus Martinelli

PRESENTING CLINICAL SIGNS

Referred for CT due to chronic, progressive LTL lameness. Plain appears localized to the left shoulder. Acute onset soft tissue swelling over the cranio-lateral aspect of the shoulder noticed within the past 24-48 hours. Aspirates obtained from multiple regions of the SQ mass yielded only peripheral blood.

SPECIES

Canine

Abnormal PE/Chem/CBC/UA Results: Mildly elevated CK =235 (10-200) U/L, NSF otherwise

BREED

Rottweiler Mix

COMPUTED TOMOGRAPHY OF THE RIGHT HUMERUS

A high resolution pre- and post-contrast CT study of the right proximal humerus is provided for review.

SEX

MN

COMPUTED TOMOGRAPHIC FINDINGS

The right proximal humeral epi-, meta- and diaphysis present an ill-defined zone of permeative osteolytic lesion and immature periosteal new bone formation – most accentuated in the caudal aspect of the proximal humerus. Post contrast administration a circumferential heterogeneous contrast enhancing soft tissue mass is centered on the proximal right humeral metaphysis/epiphysis.

AGE

8 Years

The right axillary lymph node is prominent.

INTERPRETED BY

Sebastian Schaub, DVM
Dr. med. vet. DipECVDI

The pictured cranioventral aspects of the lung parenchyma are within normal limits, but small region with dystelectasis.

COMPUTED TOMOGRAPHIC DIAGNOSIS

- Monostotic mixed osteolytic & osteoproliferative lesion right proximal humerus with accompanying soft tissue mass
- Lymphadenopathy right axillary lymph node

HOSPITAL NAME

Healing Spirit Animal
Wellness

INTERPRETATION OF THE FINDINGS & FURTHER RECOMMENDATIONS

The findings are compatible with primary osseous neoplasia originating from the right humerus and potentials include osteosarcoma, chondrosarcoma, hemangiosarcoma, round cell tumor, other. Repeating FNA samples or (bone)biopsy might be used as advanced diagnostic tests.

REFERRING VET

Amanda Dossett

The prominent right axillary lymph node is equivocal for metastatic spread versus reactive hyperplasia.

INVOICE

49332

Recommend full tumor staging.

DATE

12-31-21



PATIENT

Cyrus Martinelli

SPECIES

Canine

BREED

Rottweiler Mix

SEX

MN

AGE

8 Years

INTERPRETED BY

Sebastian Schaub, DVM
Dr. med. vet. DipECVDI

HOSPITAL NAME

Healing Spirit Animal
Wellness

REFERRING VET

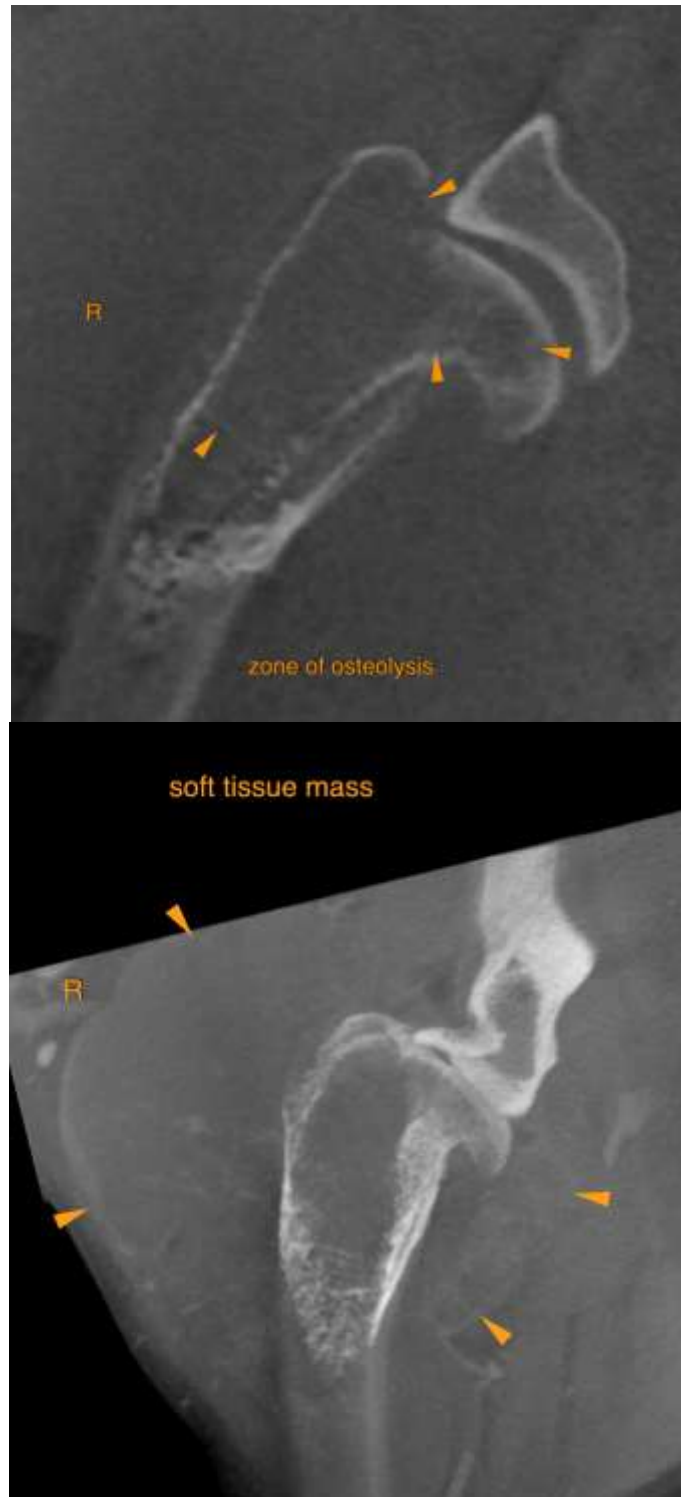
Amanda Dossett

INVOICE

49332

DATE

12-31-21





PATIENT

Cyrus Martinelli

The information and recommendations provided are based on the images presented by the referring veterinarian. No evaluation can be communicated regarding pathology that was not visible in the image/video clips provided.

SPECIES

Canine

Thank you for this referral. If the clinical or image interpretation does not parallel your findings or if I can be of any further assistance please contact me.

Sebastian Schaub, Sebastian Schaub, DVM, Dr. med. vet. DipECVDI
sebast.schaub@gmail.com

BREED

Rottweiler Mix

SEX

MN

AGE

8 Years

INTERPRETED BY

Sebastian Schaub, DVM
Dr. med. vet. DipECVDI

HOSPITAL NAME

Healing Spirit Animal
Wellness

REFERRING VET

Amanda Dossett

INVOICE

49332

DATE

12-31-21