



## PATIENT

Ryder Gieche

## SPECIES

Canine

## BREED

Cattle Dog Mix

## SEX

Neutered

## AGE

3Y, 3M

## WEIGHT

42.68

## INTERPRETED BY

Sebastian Schaub, DVM  
Dr. med. vet.  
DipECVDI

## IMAGING PERFORMED BY

Carissa Hayden

## HOSPITAL NAME

Elizabeth Animal  
Hospital

## REFERRING VET

Leon Anderson, DVM

## INVOICE

73143

## DATE

12-30-25

## PRESENTING CLINICAL SIGNS

-This morning around 2am he started to have a dry hacking and cough. -He had this in the past, and it went away with time. -This time when he hacks, he will have some clear liquid come up with it. Abnormal PE/Chem/CBC/UA Results: PE: Respiratory System: Mildly harsh lung sounds, not wet. No cough elicited with coupage. CBC: Reticulocytes 15 K/uL, Reticulocyte Hemoglobin 23.5pg, Monocytes 1.045 K/uL CHEM: Normal UA: pH 7.0, Specific Gravity >1.050

## RADIOGRAPHIC STUDY OF THE NECK

Radiographs of the neck in three image planes are provided for review.

## RADIOGRAPHIC FINDINGS

The larynx has the expected anatomy.

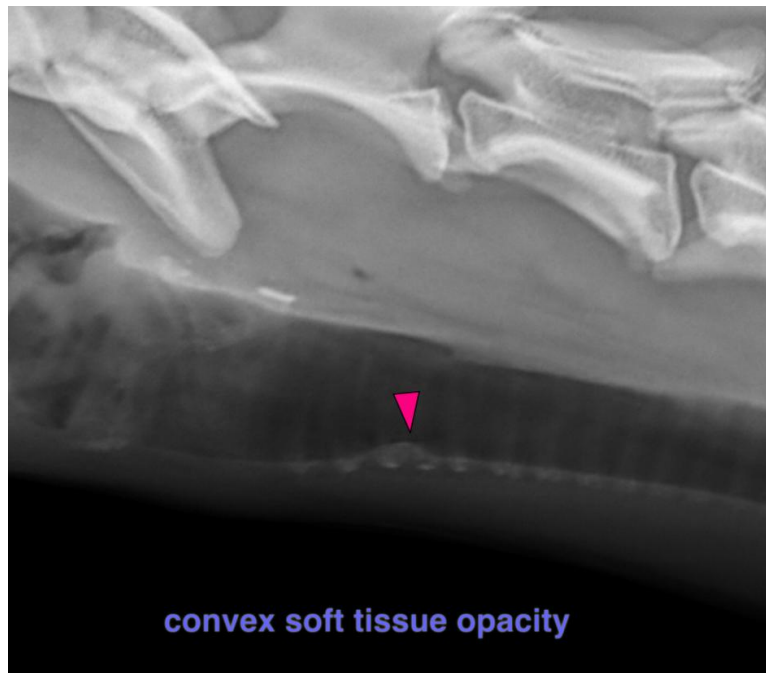
In the left lateral view of the neck, level with the caudal third of the vertebral body of C2, the ventral tracheal wall presents focal mild convex shaped soft tissue opacity is seen – not appreciated in the right lateral view. The remainder of the osseous and soft tissue structures of the neck are within normal limits.

## RADIOGRAPHIC DIAGNOSIS

- Focal intraluminal soft tissue opacity ventral tracheal wall, level C2

## INTERPRETATION OF THE FINDINGS & FURTHER RECOMMENDATIONS

The focal intraluminal soft tissue opacity of the ventral tracheal wall can present some mucus on the tracheal wall; less likely differentials are granuloma or soft tissue neoplasm originating from the tracheal wall.





## PATIENT

Ryder Gieche

## SPECIES

Canine

## BREED

Cattle Dog Mix

## SEX

Neutered

## AGE

3Y, 3M

## WEIGHT

42.68

## INTERPRETED BY

Sebastian Schaub, DVM  
Dr. med. vet.  
DipECVDI

## IMAGING PERFORMED BY

Carissa Hayden

## HOSPITAL NAME

Elizabeth Animal  
Hospital

## REFERRING VET

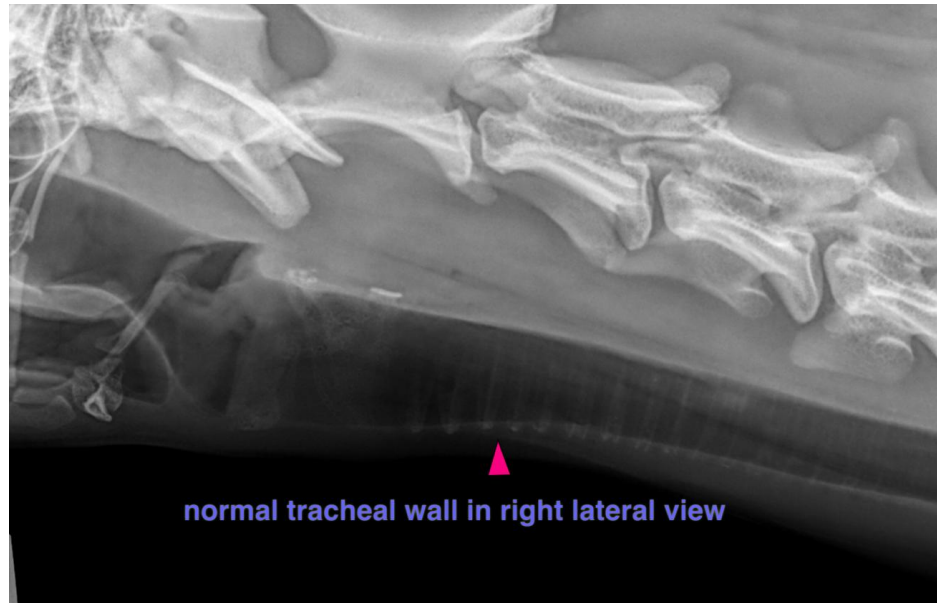
Leon Anderson, DVM

## INVOICE

73143

## DATE

12-30-25



The information and recommendations provided are based on the images presented by the referring veterinarian/sonographer. No evaluation can be communicated regarding pathology that was not visible in the image/video clips provided.

Thank you for this referral. If the clinical or image interpretation does not parallel your findings or if I can be of any further assistance please contact me.

**Sebastian Schaub**, Sebastian Schaub, DVM, Dr. med. vet. DipECVDI  
[info@sonopath.com](mailto:info@sonopath.com)