



PATIENT

Frankie Kennedy

SPECIES

Canine

BREED

French Bulldog

SEX

Neutered Male

AGE

11Y

WEIGHT

10.1kg

INTERPRETED BY

Sebastian Schaub, DVM
Dr. med. vet.
DipECVDI

IMAGING PERFORMED BY

Hector B.

HOSPITAL NAME

CARE Surgery Center

REFERRING VET

Dr. Samantha
Parkinson

INVOICE

73146

DATE

12-30-25

PRESENTING CLINICAL SIGNS

Concern for right sided epistaxis and an abdominal mass that was found incidentally on radiographs at BluePearl Emergency during work-up of hyporexia + vomiting. Epistaxis has not recurred since 12/24/25. Patient taken to surgery for spenectomy on 12/30/25.

Abnormal PE/Chem/CBC/UA Results: RBC 4.09 M/uL, HCT 26.6%, HGB 8.9 g/dL, Retic 128.4 K/uL, Lym 0.82 K/uL, MPV 14 fL

COMPUTED TOMOGRAPHY OF THE SKULL, THORAX AND ABDOMEN

A high resolution pre- and post-contrast CT study of the skull and abdomen and a post-contrast CT study of the thorax is provided for review.

COMPUTED TOMOGRAPHIC FINDINGS

Skull

Multiple teeth are absent. Triadan 301 presents advanced resorptive lesions of the root.

The alveolar process of the right maxillary bone and right zygomatic bone present extensive permeative osteolysis – from the level of triadan 104 to 108. A mild to moderate soft tissue swelling with a homogeneous contrast enhancement pattern is centered on the alveolar process of the right maxillary bone – protruding into the oral cavity and nasal cavity.

The nasal cavity presents the expected aerated spaces between thin & even conchae and turbinates with smooth mucosal lining.

Both temporomandibular joints present congruent joint spaces with even subchondral bone surfaces and are considered within normal limits.

Both tympanic bullae are aerated, the mucosal lining is not seen, the bony wall is smooth and thin. The external ear canals are within normal limits.

The brain presents no deviation from normal anatomy and symmetry. The brain parenchyma is homogeneous and within normal limits for attenuation and distribution of contrast enhancement. The ventricular system is non-dilated and symmetric.

The submandibular and medial retropharyngeal lymph nodes are small and elongated with a normal short-to-long-axis-ratio is < 0.5, the attenuation and contrast enhancement pattern is uniform.

Thorax

Congenital malformation of multiple thoracic vertebra is appreciated along with multifocal spondylosis formation.

The xiphoid process of the sternum is split in the midline.

In the subcutaneous tissue along the thoracic and abdominal wall, multiple well-defined, soft tissue nodules are seen.

In the cranioventral aspect of the mediastinum, an ovoid shaped, uniform soft tissue attenuating and contrast enhancing mass is seen; measuring 2.5 x 1.9 x 3.7 cm.

The sternal, cranial mediastinal and tracheobronchial lymph nodes are small elongated with a normal short-to-long-axis-ratio is < 0.5, the attenuation and contrast enhancement pattern is uniform and considered within normal limits.

The cardiovascular structures including the pulmonary vasculature are within normal limits.



PATIENT

Frankie Kennedy

SPECIES

Canine

BREED

French Bulldog

SEX

Neutered Male

AGE

11Y

WEIGHT

10.1kg

INTERPRETED BY

Sebastian Schaub, DVM
Dr. med. vet.
DipECVDI

IMAGING PERFORMED BY

Hector B.

HOSPITAL NAME

CARE Surgery Center

REFERRING VET

Dr. Samantha
Parkinson

INVOICE

73146

DATE

12-30-25

The bronchial tree presents with regular branching and tapers uniformly towards the periphery as expected, the bronchial walls are thin and smooth. The bronchus-to-artery ratio is within normal limits.

Throughout the lung parenchyma, multiple, randomly distributed 'Ditzel' are seen.

Small incidental gas pockets are seen within the esophageal lumen; there is no evidence of abnormal dilation.

Abdomen

The ventral aspects of the peritoneal fat present mild soft tissue striation.

Both kidneys present within normal limits for size, shape and organ architecture. After contrast administration, a bilaterally symmetric and uniform nephro- and pyelogram is noted.

The adrenal glands are within normal limits for size, shape and organ architecture.

The liver presents with normal shape, even surface, uniformly attenuating parenchyma and homogeneous contrast enhancement, unremarkable.

Originating from the caudal extremity of the spleen, a well-defined, globoid shaped, uniform soft tissue attenuating and heterogeneous contrast enhancing mass is seen; measuring 9.5 cm in diameter.

The hepatic and lienal lymph nodes are moderately prominent and rounded.

The pancreas is evenly contoured; the pancreatic parenchyma is homogeneous and presents uniform contrast enhancement.

The position, delineation, wall and content of the gastrointestinal tract are considered within normal limits throughout.

The bony and surrounding soft tissue structures reveal no abnormalities.

COMPUTED TOMOGRAPHIC DIAGNOSIS

- Polyostotic aggressive osteolytic lesions right maxillary & zygomatic bone with associated mild soft tissue swelling
- Cranioventral mediastinal soft tissue mass
- Large splenic soft tissue mass with secondary mild peritonitis
- Lymphadenopathy hepatic and lienal lymph nodes
- Multiple Ditzel throughout the lung parenchyma
- Multiple non-specific subcutaneous soft tissue nodules
- Bifid xiphoid process of the sternum
- Congenital malformation multiple thoracic vertebra
- Spondylosis deformans

INTERPRETATION OF THE FINDINGS & FURTHER RECOMMENDATIONS

The aggressive bone lesion of the right maxillary bone is consistent with neoplastic transformation – such as primary osseous neoplasia (e.g. osteosarcoma, melanoma, squamous cell carcinoma) or metastatic disease of the abdominal/thoracic masses. The invasion of the nasal cavity does explain the right sided epistaxis.

Differentials for the splenic mass include primary soft tissue neoplasia (e.g. sarcoma, round cell tumor) or benign nodular hyperplasia versus splenic hematoma. The enlarged cranial abdominal lymph nodes and cranioventral mediastinal soft tissue mass are significantly increasing the odds for neoplastic origin.



PATIENT

Frankie Kennedy

SPECIES

Canine

BREED

French Bulldog

SEX

Neutered Male

AGE

11Y

WEIGHT

10.1kg

INTERPRETED BY

Sebastian Schaub, DVM
Dr. med. vet.
DipECVDI

IMAGING PERFORMED BY

Hector B.

HOSPITAL NAME

CARE Surgery Center

REFERRING VET

Dr. Samantha
Parkinson

INVOICE

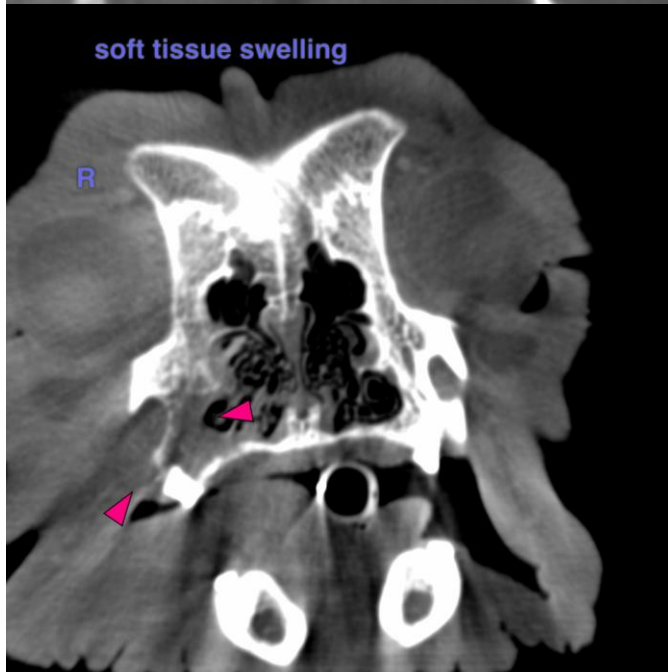
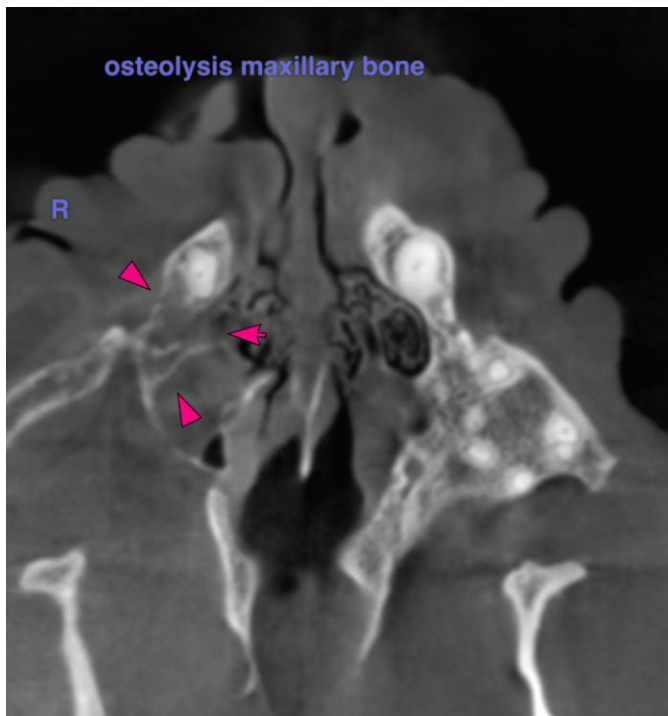73146

DATE

12-30-25

FNA sampling of the maxillary mass, cranioventral mediastinal mass, enlarged cranial abdominal lymph nodes ± splenic mass can be performed for specification.

The appreciated Ditzels are commonly nonspecific small soft tissue nodules with unknown dignity and differentials would include fibrosis vs. osteomas (prioritized), granuloma, mucous impaction, pneumonia, metastasis(unlikely).





PATIENT

Frankie Kennedy

SPECIES

Canine

BREED

French Bulldog

SEX

Neutered Male

AGE

11Y

WEIGHT

10.1kg

INTERPRETED BY

Sebastian Schaub, DVM
Dr. med. vet.
DipECVDI

IMAGING PERFORMED BY

Hector B.

HOSPITAL NAME

CARE Surgery Center

REFERRING VET

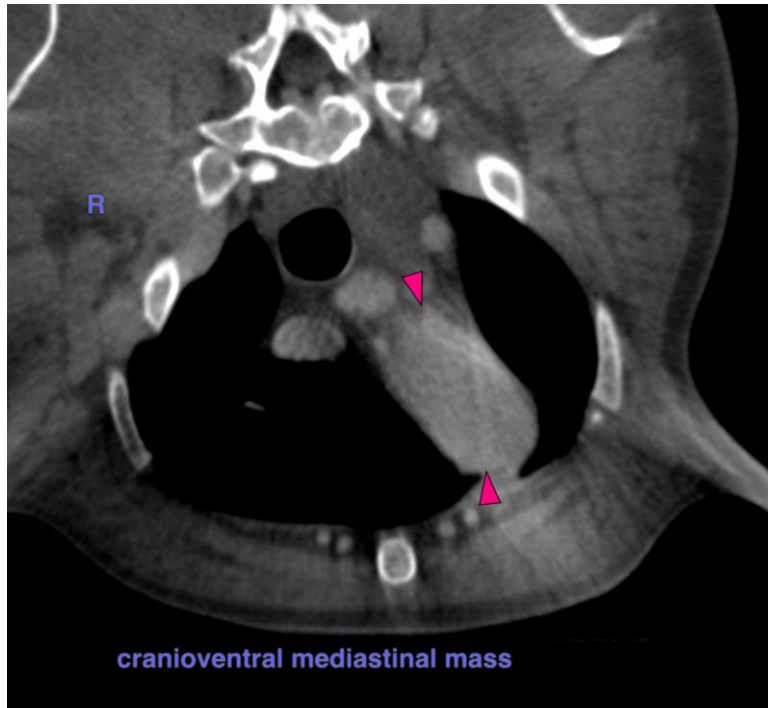
Dr. Samantha
Parkinson

INVOICE

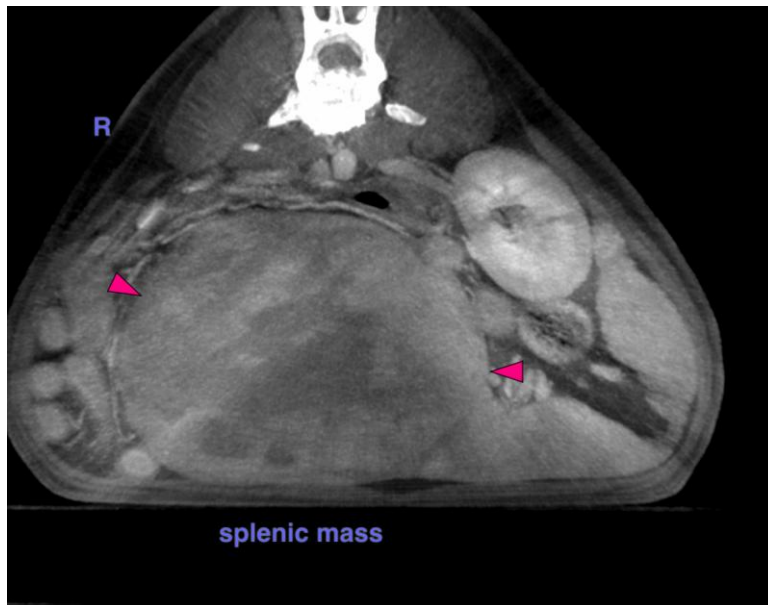
73146

DATE

12-30-25



cranioventral mediastinal mass



splenic mass



PATIENT

Frankie Kennedy

SPECIES

Canine

BREED

French Bulldog

SEX

Neutered Male

AGE

11Y

WEIGHT

10.1kg

INTERPRETED BY

Sebastian Schaub, DVM
Dr. med. vet.
DipECVDI

IMAGING PERFORMED BY

Hector B.

HOSPITAL NAME

CARE Surgery Center

REFERRING VET

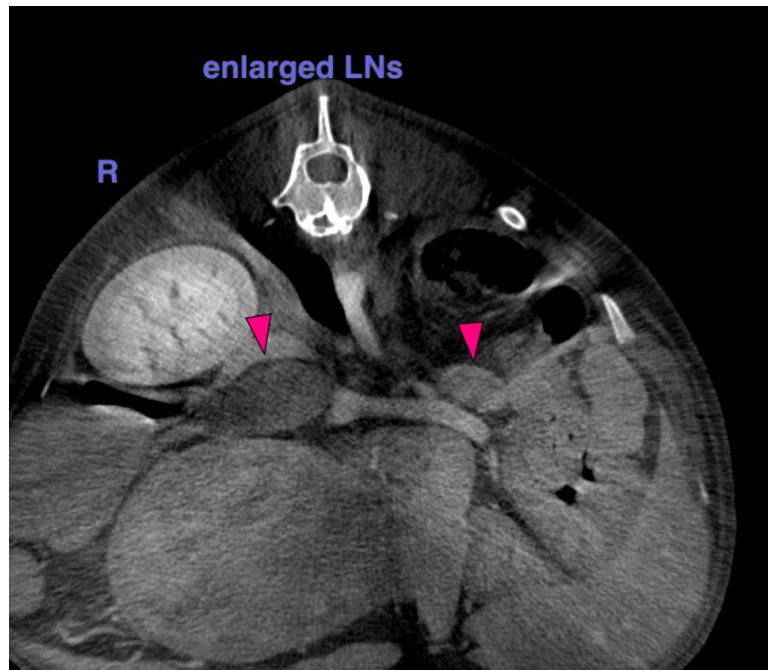
Dr. Samantha
Parkinson

INVOICE

73146

DATE

12-30-25



The information and recommendations provided are based on the images presented by the referring veterinarian/sonographer. No evaluation can be communicated regarding pathology that was not visible in the image/video clips provided.

Thank you for this referral. If the clinical or image interpretation does not parallel your findings or if I can be of any further assistance please contact me.

Sebastian Schaub, Sebastian Schaub, DVM, Dr. med. vet. DipECVDI
info@sonopath.com