



PATIENT PRESENTING CLINICAL SIGNS

Shadow Haughey History: Pet has history of pemphigus over the sinus cavity left greater than right. The combination of gingivitis with chronic L-sided more pronounced pemphigoid changes raises concern of possible root abscessation which may prolong signs of pemphigus. Please evaluate sinus cavity and dental health.

SPECIES

Canine

Abnormal PE/Chem/CBC/UA Results:

COMPUTED TOMOGRAPHIC STUDY OF THE SKULL

BREED

A high-resolution plain CT study of the skull is provided for review.

Australian Shepherd

COMPUTED TOMOGRAPHIC FINDINGS

SEX

The pictured parts of the dentition are complete and unremarkable in all jaw quadrants.

Neutered Male

The nasal cavity presents the expected aerated spaces between thin & even conchae and turbinates with smooth mucosal lining.

AGE

Both temporomandibular joints present congruent joint spaces with even subchondral bone surfaces and are considered within normal limits.

9 Years

Both tympanic bullae are aerated, the mucosal lining is not seen, the bony wall is smooth and thin. The external ear canals are within normal limits.

INTERPRETED BY

Sebastian Schaub,
DVM Dr. med. vet.
DipECVDI

COMPUTED TOMOGRAPHIC DIAGNOSIS

- Normal splanchnocranium

HOSPITAL NAME

Cranberry Holistic PC

INTERPRETATION OF THE FINDINGS & FURTHER RECOMMENDATIONS

The CT study presents without abnormalities, there are no signs of periodontal disease/tooth root abscessation.

REFERRING VET

Dr. Cynthia Maro

INVOICE

20311

DATE

12/30/22



PATIENT

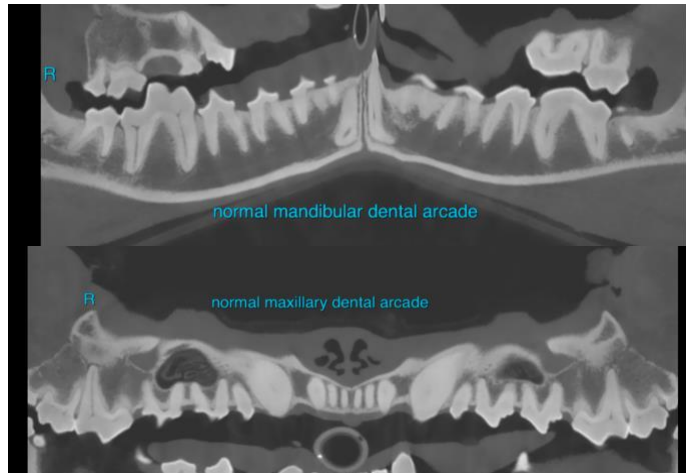
Shadow Haughey

SPECIES

Canine

BREED

Australian Shepherd



SEX

Neutered Male

The information and recommendations provided are based on the images presented by the referring veterinarian/sonographer. No evaluation can be communicated regarding pathology that was not visible in the image/video clips provided.

AGE

9 Years

Thank you for this referral. If the clinical or image interpretation does not parallel your findings or if I can be of any further assistance please contact me.

Sebastian Schaub, Sebastian Schaub, DVM, Dr. med. vet. DipECVDI
sebast.schaub@gmail.com

INTERPRETED BY

Sebastian Schaub,
DVM Dr. med. vet.
DipECVDI

HOSPITAL NAME

Cranberry Holistic PC

REFERRING VET

Dr. Cynthia Maro

INVOICE

20311

DATE

12/30/22