



PATIENT PRESENTING CLINICAL SIGNS

PATIENT Gracie Humphrey
SPECIES Canine
BREED Shepherd Mix

History: Pt presented for possible puncture wound in the mouth. O's had noted pt had malodorous mouth about 5-7 days ago and that pt was progressively painful with the mouth as well. Abnormal PE/Chem/CBC/UA Results: Pt was anesthetized for possible puncture wound surgery/dental procedure but the teeth looked fairly unremarkable, rather an ulcerated swelling was noted caudal to the last molar of lower right arcade. The area was ill-defined, no obvious mass, but very firm and malodorous. The gingiva/mucus membranes were mildly ulcerated focally, with erythema and swelling in this area (caudal to #411. Pt had developed changes to the right eye as well 1-2 days before presenting (third eyelid was elevated, mild episcleral injection). Pt had decreased appetite/anorexia and mild lethargy 1-2 days before presenting as well. CBC/chemistry: Leukocytosis (23.83 K/uL, normal range 5.05-16.76), characterized by neutrophilia (19.57 K/uL, norm 2.95-11.64), and monocytosis (2.20 K/uL, norm 0.16-1.12). Decreased BUN (5 mg/dL, norm 7-27), and hyperglobulinemia (4.6 g/dL, norm 2.5-4.5).

SEX COMPUTED TOMOGRAPHIC STUDY OF THE SKULL

SEX Spayed Female
 A high resolution pre- and post-contrast CT study of the skull is provided for review.

AGE COMPUTED TOMOGRAPHIC FINDINGS

AGE 6 Years
 The pictured parts of the dentition are complete and unremarkable in all jaw quadrants.

INTERPRETED BY

Sebastian Schaub,
 DVM Dr. med. vet.
 DipECVDI

In the right retrobulbar space, an ill-defined soft tissue swelling is appreciated. The volume of the rostral segment of the right temporal muscle and the right masseter muscle is moderately increased and present a heterogeneous contrast enhancement pattern. The right zygomatic salivary gland is moderately swollen. The right ocular bulb is deviated rostrally and dorsally by the mass effect.

In both nasal cavities, a small amount of fluid attenuating material is attached to the nasal mucosal lining.

HOSPITAL NAME

Petroglyph AH

Both temporomandibular joints present congruent joint spaces with even subchondral bone surfaces and are considered within normal limits.

REFERRING VET

Amanda Espinosa

Both tympanic bullae are aerated, the mucosal lining is not seen, the bony wall is smooth and thin. The external ear canals are within normal limits.

The brain presents no deviation from normal anatomy and symmetry. The brain parenchyma is homogeneous and within normal limits for attenuation and distribution of contrast enhancement. The ventricular system is non-dilated and symmetric.

INVOICE

20314

The right medial retropharyngeal lymph node and the right mandibular lymph nodes are prominent and present a heterogeneous contrast enhancement pattern – the surrounding fat presents moderate fat-stranding.

DATE

12/30/22



PATIENT COMPUTED TOMOGRAPHIC DIAGNOSIS

- Gracie Humphrey
- Right sided retrobulbar steatitis and myositis
 - Sialadenitis right zygomatic salivary gland
 - Secondary right sided exophthalmos
- SPECIES**
- Lymphadenopathy right mandibular and medial retropharyngeal lymph nodes with surrounding cellulitis
- Canine
- Mild rhinitis

INTERPRETATION OF THE FINDINGS & FURTHER RECOMMENDATIONS

BREED

Shepherd Mix

The CT study is consistent with right sided retrobulbar steatitis and myositis without distinct abscess formation, secondary right sided exophthalmos and reactive hyperplasia of the tributary lymph nodes. An underlying cause for the retrobulbar inflammatory changes is not appreciated and preceding perforating insult or migrating foreign body are considerations. As there is a lack of distinct cavitory lesion, conservative management by the means of antimicrobial therapy appears beneficial in first instance – if clinical signs reoccur or are refractory to therapy, surgical management should be considered.

SEX

Spayed Female

AGE

6 Years

INTERPRETED BY

Sebastian Schaub,
DVM Dr. med. vet.
DipECVDI

HOSPITAL NAME

Petroglyph AH

REFERRING VET

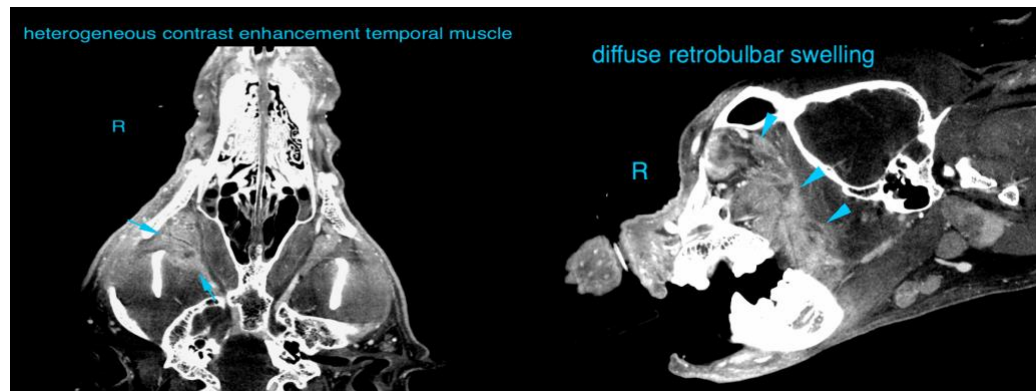
Amanda Espinosa

INVOICE

20314

DATE

12/30/22



The information and recommendations provided are based on the images presented by the referring veterinarian/sonographer. No evaluation can be communicated regarding pathology that was not visible in the image/video clips provided.

Thank you for this referral. If the clinical or image interpretation does not parallel your findings or if I can be of any further assistance please contact me.

Sebastian Schaub, Sebastian Schaub, DVM, Dr. med. vet. DipECVDI
sebast.schaub@gmail.com



PATIENT

Gracie Humphrey

SPECIES

Canine

BREED

Shepherd Mix

SEX

Spayed Female

AGE

6 Years

INTERPRETED BY

Sebastian Schaub,
DVM Dr. med. vet.
DipECVDI

HOSPITAL NAME

Petroglyph AH

REFERRING VET

Amanda Espinosa

INVOICE

20314

DATE

12/30/22