



## PATIENT

Merlin Donnell

## SPECIES

Canine

## BREED

Shih Tzu

## SEX

Neutered Male

## AGE

9Y

## WEIGHT

10.10kgs

## INTERPRETED BY

Sebastian Schaub, DVM  
Dr. med. vet.  
DipECVDI

## IMAGING PERFORMED BY

Josh

## HOSPITAL NAME

CARE Surgery Center

## REFERRING VET

Dr. Keats

## INVOICE

72852

## DATE

12-3-25

## PRESENTING CLINICAL SIGNS

Left anal sac mass discovered by groomer on 12/2

## COMPUTED TOMOGRAPHY OF THE THORAX AND ABDOMEN

A high resolution pre- and post-contrast CT study of the thorax and abdomen is provided for review.

## COMPUTED TOMOGRAPHIC FINDINGS

### Thorax

Along the thoracic spine, multifocal spondylosis formation is seen.

The periarticular bones of both shoulder joints present mild to moderate osteophyte new bone formation. At the caudal aspect of the glenoid cavity bilaterally, an isolated ovoid shaped ossification center is appreciated.

The sternal, cranial mediastinal and tracheobronchial lymph nodes are small elongated with a normal short-to-long-axis-ratio is < 0.5, the attenuation and contrast enhancement pattern is uniform and considered within normal limits.

The cardiovascular structures including the pulmonary vasculature are within normal limits.

The bronchial tree presents with regular branching and tapers uniformly towards the periphery as expected, the bronchial walls are thin and smooth. The bronchus-to-artery ratio is within normal limits.

The lung parenchyma presents the expected architecture and attenuation behavior.

Small incidental gas pockets are seen within the esophageal lumen; there is no evidence of abnormal dilation.

### Abdomen

The serosal fat presents normal attenuation behavior. There is no evidence of peritoneal effusion or peritonitis.

Both kidneys present within normal limits for size, shape and organ architecture. After contrast administration, a bilaterally symmetric and uniform nephro- and pyelogram is noted.

Nodular enlargement of both adrenal glands is appreciated, measuring up to 1.8 x 2.2 x 3.0 cm (left)/12 x 16 x 2.5 cm (right)

Both liver and spleen present with normal shape, even surface, uniformly attenuating parenchyma and homogeneous contrast enhancement, unremarkable.

The pancreas is evenly contoured; the pancreatic parenchyma is homogeneous and presents uniform contrast enhancement.

The position, delineation, wall and content of the gastrointestinal tract are considered within normal limits throughout.

The anal region is cropped by the field of view.

The hypogastric and sublumbar lymph nodes are small.

In the subcutaneous tissue dorsal to L6, a well-defined, ovoid shaped soft tissue nodule is seen; measuring up to 6 mm.



## PATIENT

Merlin Donnell

## SPECIES

Canine

## BREED

Shih Tzu

## SEX

Neutered Male

## AGE

9Y

## WEIGHT

10.10kgs

## INTERPRETED BY

Sebastian Schaub, DVM  
Dr. med. vet.  
DipECVDI

## IMAGING PERFORMED BY

Josh

## HOSPITAL NAME

CARE Surgery Center

## REFERRING VET

Dr. Keats

## INVOICE

72852

## DATE

12-3-25

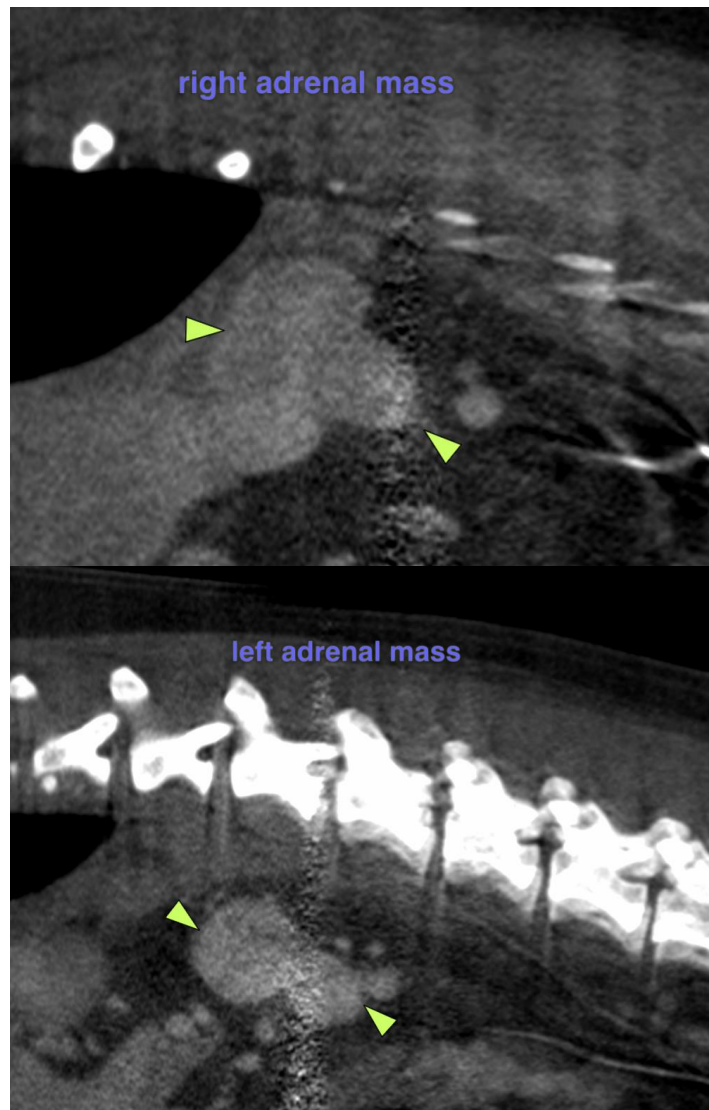
## COMPUTED TOMOGRAPHIC DIAGNOSIS

- Bilateral adrenal soft tissue mass without vascular invasion
- Non-specific subcutaneous soft tissue nodule dorsal L6
- Osteoarthritis shoulder joints
- Spondylosis deformans thoracic spine
- No evidence of pulmonary metastatic disease
- No evidence of lymphadenopathy of the hypogastric lymph nodes

## INTERPRETATION OF THE FINDINGS & FURTHER RECOMMENDATIONS

The nodular enlargement of the adrenal glands can present (non)functional macronodular hyperplasia or bilateral adrenal neoplasia – such as adenoma, adenocarcinoma, pheochromocytoma.

The CT study is negative for macroscopic metastatic disease of the described left anal sac mass.





## PATIENT

Merlin Donnell

## SPECIES

Canine

## BREED

Shih Tzu

## SEX

Neutered Male

## AGE

9Y

## WEIGHT

10.10kgs

## INTERPRETED BY

Sebastian Schaub, DVM  
Dr. med. vet.  
DipECVDI

## IMAGING PERFORMED BY

Josh

## HOSPITAL NAME

CARE Surgery Center

## REFERRING VET

Dr. Keats

## INVOICE

72852

## DATE

12-3-25

The information and recommendations provided are based on the images presented by the referring veterinarian/sonographer. No evaluation can be communicated regarding pathology that was not visible in the image/video clips provided.

Thank you for this referral. If the clinical or image interpretation does not parallel your findings or if I can be of any further assistance please contact me.

**Sebastian Schaub**, Sebastian Schaub, DVM, Dr. med. vet. DipECVDI  
[info@sonopath.com](mailto:info@sonopath.com)