



PATIENT PRESENTING CLINICAL SIGNS

Tito Leon History: Tito is a 3yr MI Chihuahua that presented for evaluation after being attacked by a dog. Radiographs showed suspect fracture of the transverse process of C4 +/- C5

SPECIES COMPUTED TOMOGRAPHIC STUDY OF THE NECK

Canine A high-resolution plain CT study of the neck is provided for review.

COMPUTED TOMOGRAPHIC FINDINGS

BREED

Chihuahua A moderate subcutaneous swelling and fat stranding is seen along right subcutaneous and intermuscular fat

SEX

The distal aspect of the right transverse process of C5 is fractured with an isolated osseous fragment caudally, measuring 4 mm in size and two small osseous fragments cranially.

Intact Male

The right medial retropharyngeal lymph node is prominent.

AGE

3 Years

COMPUTED TOMOGRAPHIC DIAGNOSIS

- Fractured right transverse process C5 with three isolated osseous fragments
- Subcutaneous swelling along the right aspect of the neck – suspect hematoma formation
- Lymphadenopathy right medial retropharyngeal lymph node – likely reactive hyperplasia

INTERPRETED BY

Sebastian Schaub,
DVM Dr. med. vet.
DipECVDI

INTERPRETATION OF THE FINDINGS & FURTHER RECOMMENDATIONS

The CT study is confirming the acute fracture of the transverse process of C5 and likely accompanying hematoma along the right aspect of neck. There is no evidence of vertebral luxation or fractures of the vertebral bodies/pedicles/lamina. Wound management and conservative management of the fractured transverse process is considered as the therapy of choice.

HOSPITAL NAME

Animal Emergency
Hospital Volusia

REFERRING VET

Alyssa Carver

INVOICE

18979

DATE

12/3/22



PATIENT

Tito Leon

SPECIES

Canine

BREED

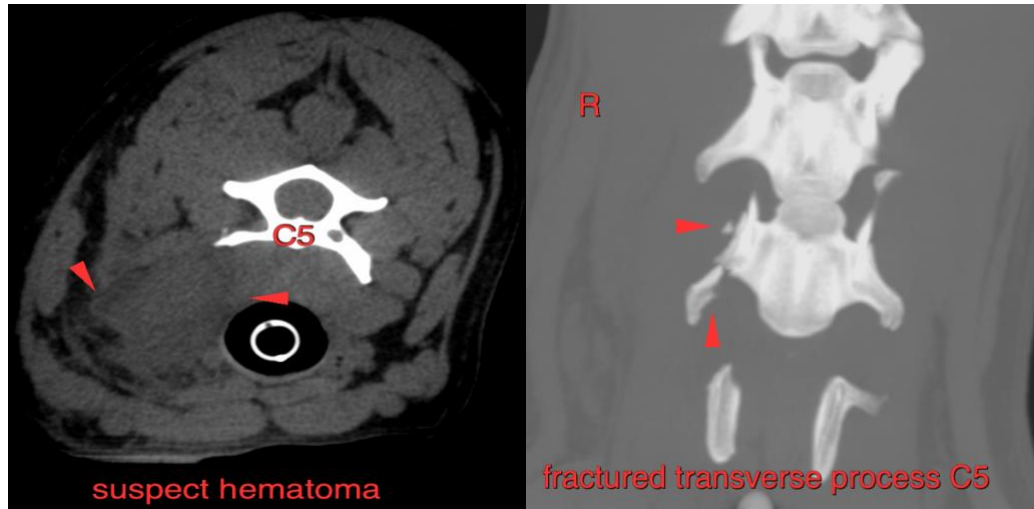
Chihuahua

SEX

Intact Male

AGE

3 Years



The information and recommendations provided are based on the images presented by the referring veterinarian/sonographer. No evaluation can be communicated regarding pathology that was not visible in the image/video clips provided.

Thank you for this referral. If the clinical or image interpretation does not parallel your findings or if I can be of any further assistance please contact me.

INTERPRETED BY

Sebastian Schaub, Sebastian Schaub, DVM, Dr. med. vet. DipECVDI
sebast.schaub@gmail.com

Sebastian Schaub,
DVM Dr. med. vet.
DipECVDI

HOSPITAL NAME

Animal Emergency
Hospital Volusia

REFERRING VET

Alyssa Carver

INVOICE

18979

DATE

12/3/22