



PATIENT

Wall-E Winstead

PRESENTING CLINICAL SIGNS

Chronic daily vomiting, palpable mass, U/S revealed mural intestinal mass, CT requested to see if mass is resectable and to check for mets

SPECIES

Canine

COMPUTED TOMOGRAPHY OF THE ABDOMEN

A high resolution pre- and post-contrast CT study of the abdomen is provided for review.

BREED

Golden Retriever

COMPUTED TOMOGRAPHIC FINDINGS

Both kidneys present within normal limits for size, shape and organ architecture. After contrast administration a bilaterally symmetric and uniform nephro- and pyelogram is noted.

SEX

MN

The adrenal glands are within normal limits for size, shape and organ architecture.

Both liver and spleen present with normal shape, even surface, uniformly attenuating parenchyma and homogeneous contrast enhancement, unremarkable.

AGE

9

The gallbladder presents a mild serrating mucosal lining.

The pancreas is evenly contoured, the pancreatic parenchyma is homogeneous and presents uniform contrast enhancement.

INTERPRETED BY

Sebastian Schaub, DVM
Dr. med. vet. DipECVDI

The stomach is moderately distended by fluid.

A small intestinal segment encompassed by a mild irregular roundish, uniform soft tissue attenuating and heterogeneous contrast enhancing mass; measuring 9.7 x 8.1 x 9.3 cm in size. The surrounding small intestinal loops are displaced centrifugally by the mass effect. The respective segment of the small intestinal loop is compressed, and the intestinal segment orally is markedly dilated by fluid. The surrounding peritoneal fat presents moderate fat-stranding, most accentuated in the cranial aspect of the peritoneal cavity with interspersed small (≤ 6 mm) soft tissue nodules.

HOSPITAL NAME

Animal Mansion

A jejunal lymph node is moderately enlarged and rounded.

REFERRING VET

Dr. Parker

The vertebral endplates of the lumbosacral junction present moderate spondylosis formation. The lumbosacral intervertebral disc is significantly protruding into the vertebral canal, occupying approximately 95% of the cross-sectional area of the vertebral canal at the same level; the caudal equine fibers level L7/S1 are displaced dorsally.

INVOICE

48768

COMPUTED TOMOGRAPHIC DIAGNOSIS

- Segmental small intestinal mechanical obstruction due to mural small intestinal mass
- Surrounding peritonitis and multiple peritoneal nodules cranial abdomen
- Lymphadenopathy jejunal lymph node
- Secondary gastric emptying disorder
- Degenerative lumbosacral stenosis
- Suspect cholecystitis
- Spondylosis deformans

DATE

12-3-21



PATIENT

Wall-E Winstead

SPECIES

Canine

BREED

Golden Retriever

SEX

MN

AGE

9

INTERPRETED BY

Sebastian Schaub, DVM
Dr. med. vet. DipECVDI

HOSPITAL NAME

Animal Mansion

REFERRING VET

Dr. Parker

INVOICE

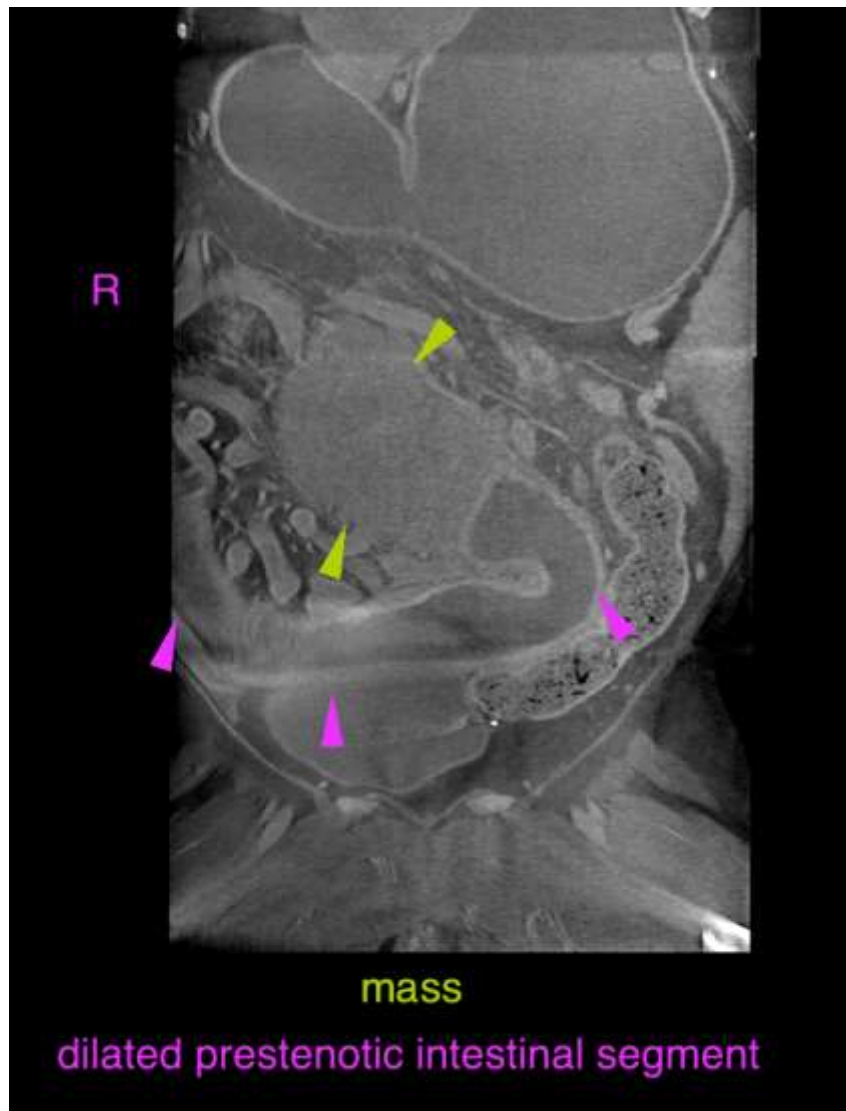
48768

DATE

12-3-21

INTERPRETATION OF THE FINDINGS & FURTHER RECOMMENDATIONS

The findings fit the history of segmental small intestinal neoplasm, causing mechanical intestinal obstruction. Differentials include sarcoma, gastro-intestinal stroma cell tumor, carcinoma or less likely round-cell tumor. Complete surgical resection of the mass appears feasible. However, the enlarged lymph node and peritoneal nodular lesions are highly concerning for metastatic spread.





PATIENT

Wall-E Winstead

SPECIES

Canine

BREED

Golden Retriever

SEX

MN

AGE

9

INTERPRETED BY

Sebastian Schaub, DVM
Dr. med. vet. DipECVDI

HOSPITAL NAME

Animal Mansion

REFERRING VET

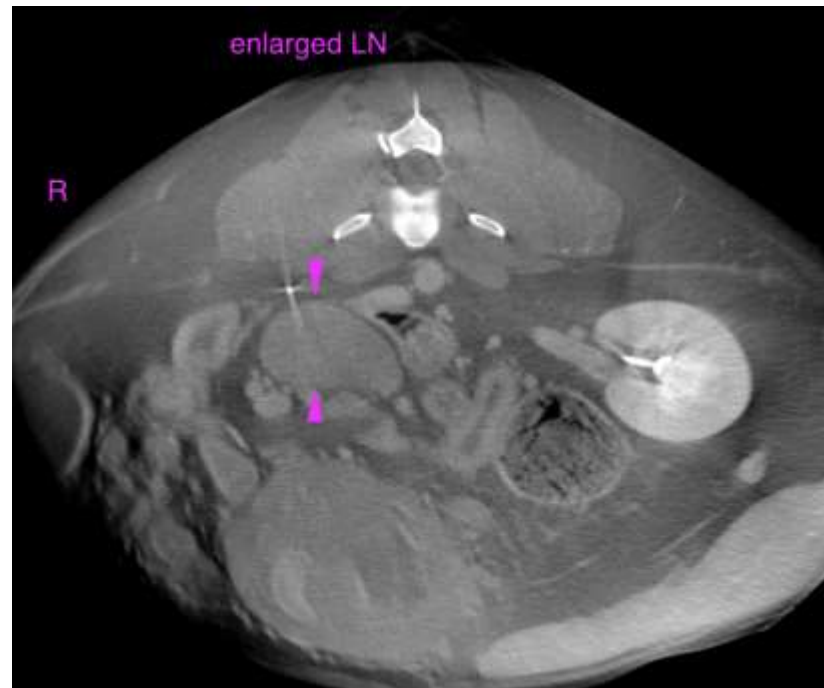
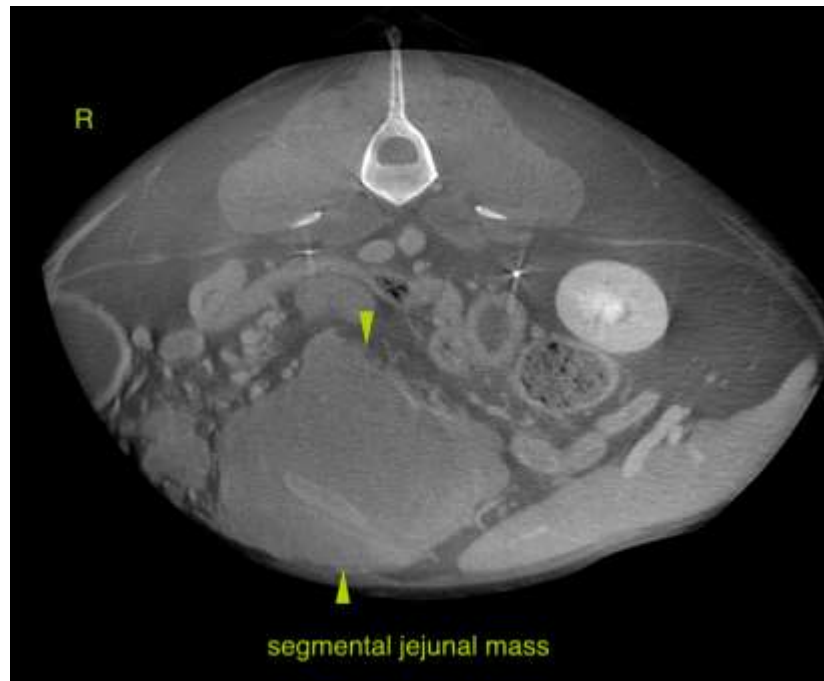
Dr. Parker

INVOICE

48768

DATE

12-3-21





PATIENT

Wall-E Winstead

SPECIES

Canine

BREED

Golden Retriever

SEX

MN

AGE

9

INTERPRETED BY

Sebastian Schaub, DVM
Dr. med. vet. DipECVDI

HOSPITAL NAME

Animal Mansion

REFERRING VET

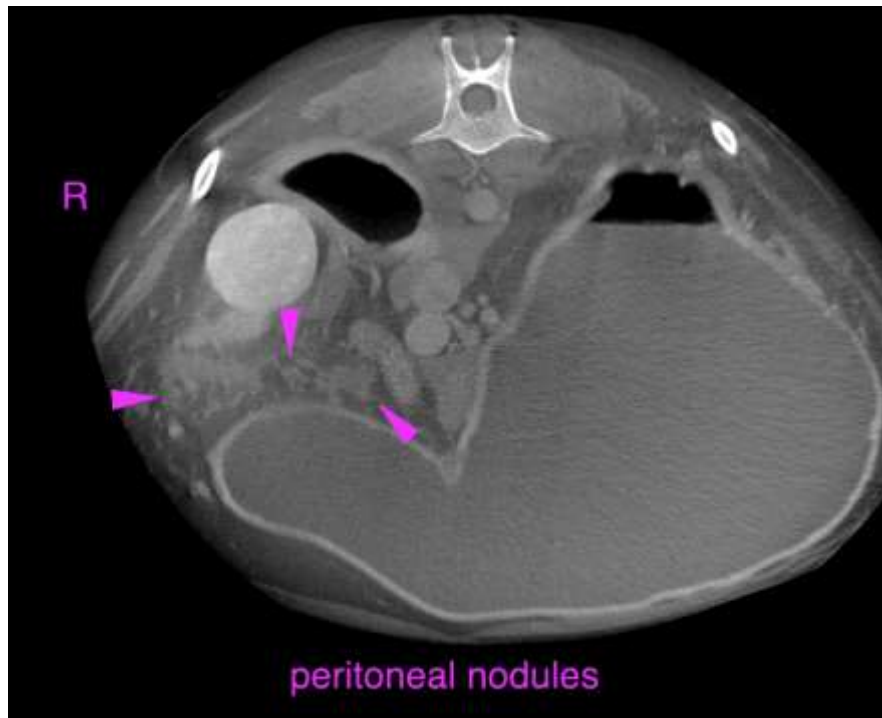
Dr. Parker

INVOICE

48768

DATE

12-3-21



The information and recommendations provided are based on the images presented by the referring veterinarian. No evaluation can be communicated regarding pathology that was not visible in the image/video clips provided.

Thank you for this referral. If the clinical or image interpretation does not parallel your findings or if I can be of any further assistance please contact me.

Sebastian Schaub, Sebastian Schaub, DVM, Dr. med. vet. DipECVDI
sebast.schaub@gmail.com