



PATIENT PRESENTING CLINICAL SIGNS

Lulu Whitson Left nasal philtrum ulcerated and missing 4mm of tissue was seen 12/20/22 and CT performed 12/29/22 O declined biopsy.

SPECIES COMPUTED TOMOGRAPHY OF THE SKULL

Feline A high resolution pre- and post-contrast CT study of the skull is provided for review.

COMPUTED TOMOGRAPHIC FINDINGS

The pictured parts of the dentition are complete and unremarkable in all jaw quadrants.

The left ala of the nasal planum is prominent, presents nodular enlargement, measuring 4 x 5 x 5 mm in size and has a heterogeneous contrast enhancement pattern. The nasal cavity presents the expected aerated spaces between thin & even conchae and turbinates with smooth mucosal lining.

SEX Post contrast administration, a filling defect is seen in the left facial vein.

SF Both temporomandibular joints present congruent joint spaces with even subchondral bone surfaces and are considered within normal limits.

AGE Both tympanic bullae are aerated, the mucosal lining is not seen, the bony wall is smooth and thin. The external ear canals are within normal limits.

12 Years

INTERPRETED BY The brain presents no deviation from normal anatomy and symmetry. The brain parenchyma is homogeneous and within normal limits for attenuation and distribution of contrast enhancement. The ventricular system is non-dilated and symmetric.

Sebastian Schaub, DVM
Dr. med. vet. DipECVDI

The submandibular and medial retropharyngeal lymph nodes are small and elongated with a normal short-to-long-axis-ratio is < 0.5, the attenuation and contrast enhancement pattern is uniform.

HOSPITAL NAME COMPUTED TOMOGRAPHIC DIAGNOSIS

Petroglyph Animal Hospital

- Nodular enlargement left ala of the nasal planum
- Thrombus formation left facial vein

REFERRING VET INTERPRETATION OF THE FINDINGS & FURTHER RECOMMENDATIONS

Dr. Eric Randall The nodular enlargement of the left ala of the nose is concerning for neoplastic transformation – such as melanoma or squamous cell carcinoma. Granuloma is a consideration as well but considered less likely. Biopsy is warranted for further definition.

INVOICE The small thrombus in the left facial vein can be paraneoplastic or secondary to focal inflammation.

55908

DATE

12-29-22



PATIENT

Lulu Whitson

SPECIES

Feline

BREED

Domestic Short Hair

SEX

SF

AGE

12 Years

INTERPRETED BY

Sebastian Schaub, DVM
Dr. med. vet. DipECVDI

HOSPITAL NAME

Petroglyph Animal
Hospital

REFERRING VET

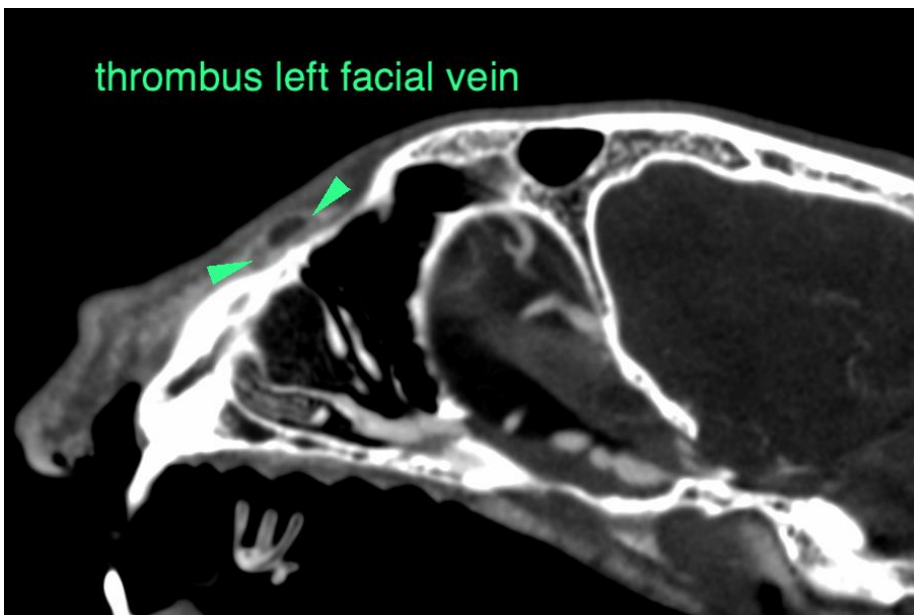
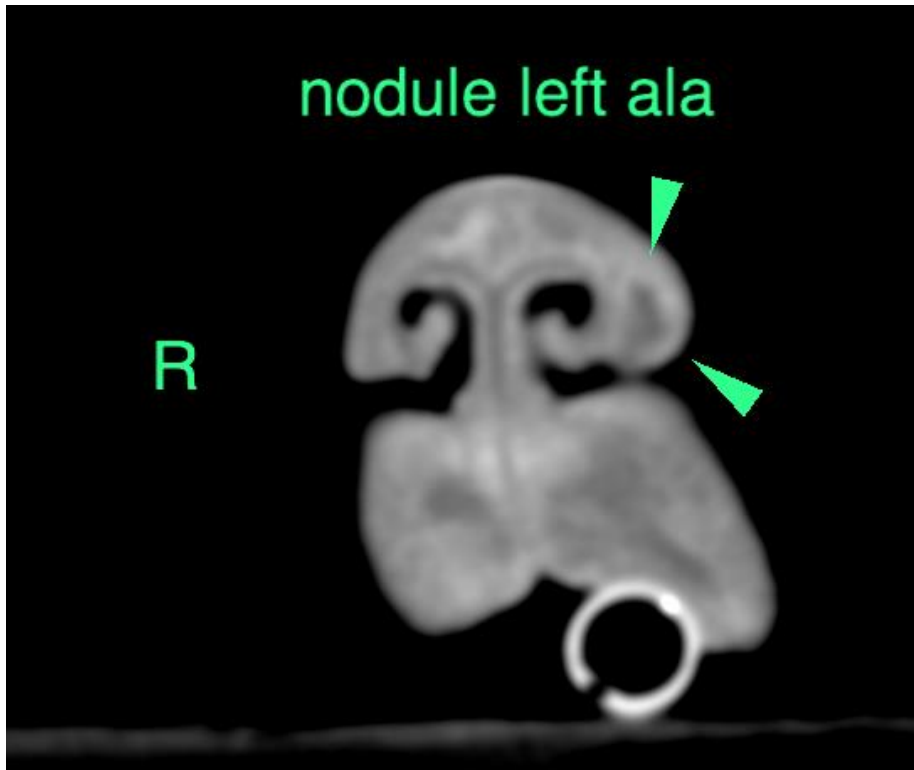
Dr. Eric Randall

INVOICE

55908

DATE

12-29-22





PATIENT

Lulu Whitson

The information and recommendations provided are based on the images presented by the referring veterinarian/sonographer. No evaluation can be communicated regarding pathology that was not visible in the image/video clips provided.

SPECIES

Feline

Thank you for this referral. If the clinical or image interpretation does not parallel your findings or if I can be of any further assistance please contact me.

Sebastian Schaub, Sebastian Schaub, DVM, Dr. med. vet. DipECVDI
sebast.schaub@gmail.com

BREED

Domestic Short Hair

SEX

SF

AGE

12 Years

INTERPRETED BY

Sebastian Schaub, DVM
Dr. med. vet. DipECVDI

HOSPITAL NAME

Petroglyph Animal
Hospital

REFERRING VET

Dr. Eric Randall

INVOICE

55908

DATE

12-29-22