



PATIENT PRESENTING CLINICAL SIGNS

Kodak Fraedrich
 chronic sneezing/respiratory signs (nasal discharge especially in the winter). Indoor/outdoor cat. Recently developed a bump on the face above the left eye. Was examined at primary vet approx. 1 month ago. Attempted a fine needle aspirate with no success. Otherwise seems to be doing well at home, eating/drinking well, normal activity.

SPECIES
 Abnormal PE/Chem/CBC/UA Results: Elevated glucose (279), otherwise CBC & chem panel were within normal limits. Hard mass above left eye starting to affect eye.
Feline

COMPUTED TOMOGRAPHY OF THE SKULL

BREED
 A high resolution pre- and post-contrast CT study of the skull is provided for review.

Maine Coon Mix COMPUTED TOMOGRAPHIC FINDINGS

Multiple teeth are absent. Retained roots of triadan 107 are appreciated in the alveolar crests, presenting signs of ankylosis and resorption.

SEX
 In the dorsal aspect of the left nasal cavity, an expansile, soft tissue attenuating and peripherally mild heterogeneous contrast enhancing mass is seen, presenting mild central amorphous mineralization. The left maxillary and nasal bone are perforated by the mass and the nasal mass is bulging into the subcutaneous tissue at the left dorsolateral aspect of the nose. In the right nasal cavity, fluid attenuating material is attached to the nasal mucosal lining. Moderate destruction of the nasal conchal structures is appreciated. The frontal sinus bilaterally contains a moderate amount of fluid attenuating material.
MN

AGE
 9.5 Years

INTERPRETED BY The right zygomatic salivary gland presents with a central small mineral attenuating body.

Sebastian Schaub, DVM
Dr. med. vet. DipECVDI Both temporomandibular joints present congruent joint spaces with even subchondral bone surfaces and are considered within normal limits.

Both tympanic bullae are aerated, the mucosal lining is not seen, the bony wall is smooth and thin. The external ear canals are within normal limits.

HOSPITAL NAME The brain presents no deviation from normal anatomy and symmetry. The brain parenchyma is homogeneous and within normal limits for attenuation and distribution of contrast enhancement. The ventricular system is non-dilated and symmetric.
Casselton Vet Service

REFERRING VET The left mandibular lymph nodes are prominent.

Trevor Bjerke COMPUTED TOMOGRAPHIC DIAGNOSIS

- Expansile, possibly cavitated, left nasal soft tissue mass
- Destructive rhinitis
- Mild lymphadenopathy left mandibular lymph nodes
- Sinusitis frontal sinus bilaterally
- Remaining roots of triadan 107
- Multiple absent teeth

INVOICE
 55886

DATE INTERPRETATION OF THE FINDINGS & FURTHER RECOMMENDATIONS

12-29-22 The expansile left nasal mass is equivocal for primary nasal neoplasia – such as osteosarcoma, chondrosarcoma, adenocarcinoma, squamous cell carcinoma, other – or as the mass appears to be cavitated a nasal mucous cyst versus nasal (mycotic) granuloma with central dystrophic



PATIENT

Kodak Fraedrich

mineralization. Biopsy of the nasal mass is advised for further definition – either by a lateral transcutaneous approach or by rhinoscopy.

SPECIES

Feline

The mild prominent mandibular lymph nodes are equivocal for metastatic spread or reactive hyperplasia – recommend FNA sampling for further differentiation.

BREED

Maine Coon Mix

SEX

MN

AGE

9.5 Years

INTERPRETED BY

Sebastian Schaub, DVM
Dr. med. vet. DipECVDI

HOSPITAL NAME

Casselton Vet Service

REFERRING VET

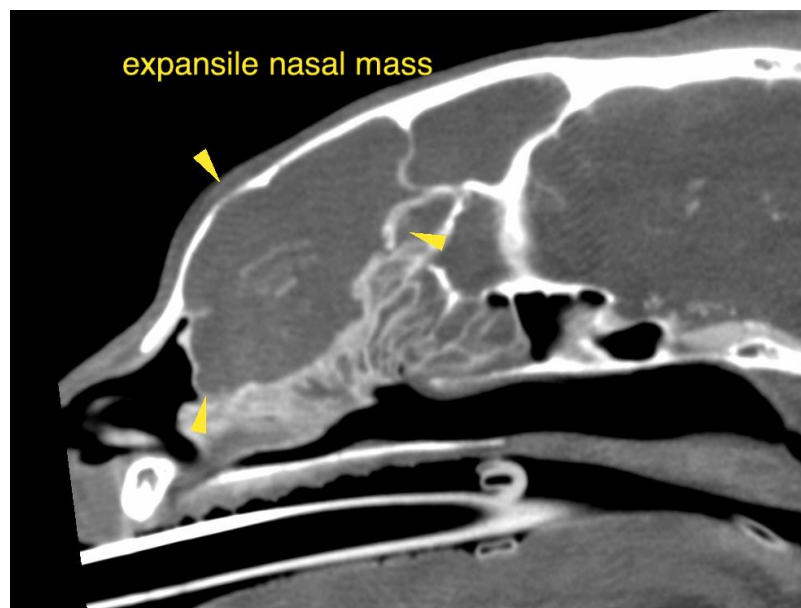
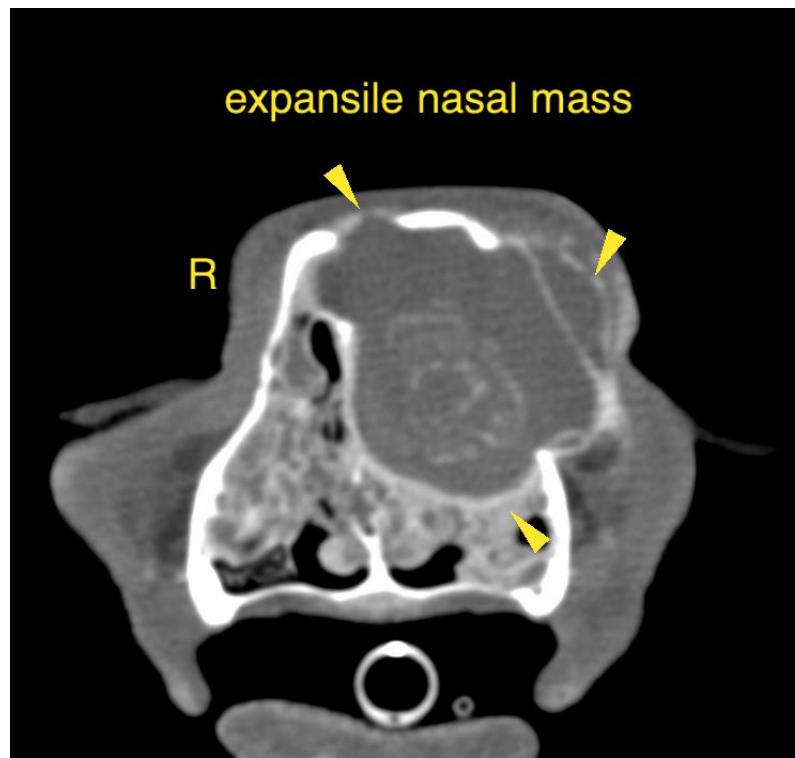
Trevor Bjerke

INVOICE

55886

DATE

12-29-22





PATIENT

Kodak Fraedrich

The information and recommendations provided are based on the images presented by the referring veterinarian/sonographer. No evaluation can be communicated regarding pathology that was not visible in the image/video clips provided.

SPECIES

Feline

Thank you for this referral. If the clinical or image interpretation does not parallel your findings or if I can be of any further assistance please contact me.

BREED

Maine Coon Mix

Sebastian Schaub, Sebastian Schaub, DVM, Dr. med. vet. DipECVDI
sebast.schaub@gmail.com

SEX

MN

AGE

9.5 Years

INTERPRETED BY

Sebastian Schaub, DVM
Dr. med. vet. DipECVDI

HOSPITAL NAME

Casselton Vet Service

REFERRING VET

Trevor Bjerke

INVOICE

55886

DATE

12-29-22