



**PATIENT PRESENTING CLINICAL SIGNS**

Indie Harris 6 month history of coughing, congestion and nasal discharge  
Abnormal PE/Chem/CBC/UA Results: Reticulocyte count 136.3

**SPECIES COMPUTED TOMOGRAPHY OF THE SKULL**

Canine A high resolution pre- and post-contrast CT study of the skull is provided for review.

**COMPUTED TOMOGRAPHIC FINDINGS**

**BREED** The pictured parts of the dentition are complete and unremarkable in all jaw quadrants.

Blue Heeler A small amount of fluid attenuating material is attached to the nasal mucosal lining bilaterally. Very mild atrophy of the nasal conchal structures is seen.

**SEX** Both temporomandibular joints present congruent joint spaces with even subchondral bone surfaces and are considered within normal limits.

NM Both tympanic bullae are aerated, the mucosal lining is not seen, the bony wall is smooth and thin. The external ear canals are within normal limits.

**AGE** The brain presents no deviation from normal anatomy and symmetry. The brain parenchyma is homogeneous and within normal limits for attenuation and distribution of contrast enhancement. The ventricular system is non-dilated and symmetric.

8 Years

**INTERPRETED BY**

Sebastian Schaub, DVM  
Dr. med. vet. DipECVDI

**COMPUTED TOMOGRAPHIC DIAGNOSIS**

- Mild rhinitis

**HOSPITAL NAME**

Petroglyph Animal Hospital

**INTERPRETATION OF THE FINDINGS & FURTHER RECOMMENDATIONS**

An underlying cause for the rhinitis is not appreciated and the presumptive diagnosis is non-specific rhinitis (e.g. allergic, lymphocytic plasmocytic, eosinophilic) ± bacterial or less likely mycotic superinfection. Rhinoscopy including biopsy can be performed as advanced diagnostic test.

**REFERRING VET**

Amanda Espinosa

**INVOICE**

55909

**DATE**

12-29-22



**PATIENT**

Indie Harris

**SPECIES**

Canine

**BREED**

Blue Heeler

**SEX**

NM

**AGE**

8 Years

**INTERPRETED BY**

Sebastian Schaub, DVM  
Dr. med. vet. DipECVDI

**HOSPITAL NAME**

Petroglyph Animal  
Hospital

**REFERRING VET**

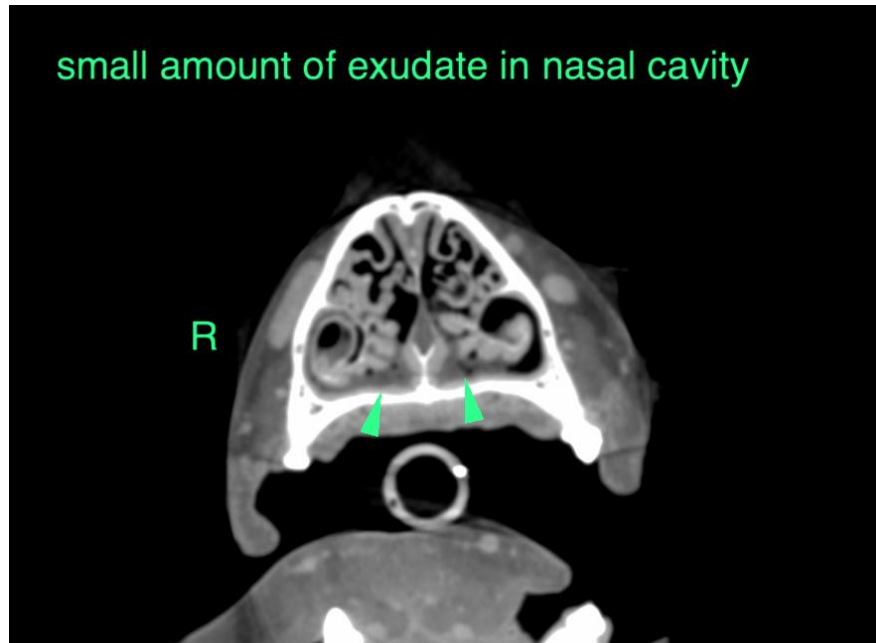
Amanda Espinosa

**INVOICE**

55909

**DATE**

12-29-22



The information and recommendations provided are based on the images presented by the referring veterinarian/sonographer. No evaluation can be communicated regarding pathology that was not visible in the image/video clips provided.

Thank you for this referral. If the clinical or image interpretation does not parallel your findings or if I can be of any further assistance please contact me.

**Sebastian Schaub**, Sebastian Schaub, DVM, Dr. med. vet. DipECVDI  
sebast.schaub@gmail.com