



PATIENT

Scarlett Dyer

PRESENTING CLINICAL SIGNS

Reason for Visit: LIMPING LEFT HIND LEG History: 15YR OLD SPAYED BEAGLE PRESENTED FOR LIMPING(SEEMS LEFT HIND). APPROX 1 WEEK AGO OWNER NOTED THAT PET DID A MOVE THAT SEEMED TO HURT HER AND SHE BEGAN LIMPING. OVER THE NEXT FEW DAYS SHE SEEMED TO GET BETTER BUT HTEN REGRESSED AGIAN YESTERDAY.

SPECIES

Canine

Abnormal PE/Chem/CBC/UA Results: CV/Respiratory: Normal heart rate and rhythm, no murmur, pulses strong and synchronous, normal bronchovesicular sounds. EENT: OU: lenticular sclerosis. AU: clear. No nasal discharge. No cough on tracheal palpation. Oral cavity: Not examined- muzzled Musculoskeletal: BCS = 5/9. Ambulatory x 4. Grade 2/5 LH lameness, painful on full extension of coxofemoral joint, negative cranial drawer and tibial thrust. Grade 2/4 R MPL Uro/Perineum: No significant lesions Abd/GI: Soft, non-painful. No masses or fluid wave palpated Lymph Nodes: No peripheral lymphadenopathy Neurological: Alert and appropriate. No significant abnormalities Skin: Good hair coat. No ectoparasites seen Mentation: QAR Hydration: N

BREED

Beagle

SEX

SF

RADIOGRAPHIC STUDY OF THE PELVIS

Radiographs of the pelvis in two imaging planes are provided for review.

AGE

15 Years, 9 Months

RADIOGRAPHIC FINDINGS

The osseous and surrounding soft tissue structures of the pelvis are within normal limits. Both coxofemoral joints present smooth osseous margins and a congruent joint space.

INTERPRETED BY

Sebastian Schaub, DVM
Dr. med. vet. DipECVDI

The patella of the right stifle joint is superimposed on the medial femoral condyle in the craniocaudal projection.

RADIOGRAPHIC DIAGNOSIS

- Right sided medial patellar luxation
- Normal pelvis/coxofemoral joints

HOSPITAL NAME

DPC Veterinary Hospital

INTERPRETATION OF THE FINDINGS & FURTHER RECOMMENDATIONS

The radiographic study of the pelvis presents without abnormalities, explaining the described clinical signs and distortion or contusion are potential differentials. The right sided medial patellar luxation is considered an incidental finding.

REFERRING VET

Dr. Rivera

INVOICE

49300

DATE

12-29-21



PATIENT

Scarlett Dyer

SPECIES

Canine

BREED

Beagle

SEX

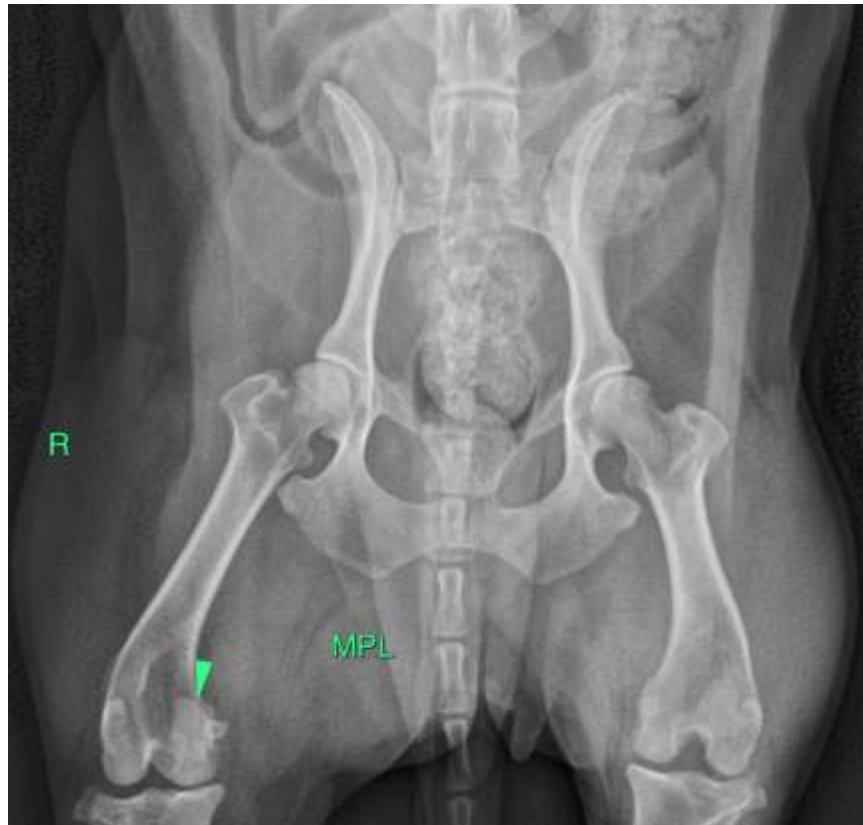
SF

AGE

15 Years, 9 Months

INTERPRETED BY

Sebastian Schaub, DVM
Dr. med. vet. DipECVDI



HOSPITAL NAME

DPC Veterinary
Hospital

REFERRING VET

Dr. Rivera

INVOICE

49300

DATE

12-29-21

The information and recommendations provided are based on the images presented by the referring veterinarian. No evaluation can be communicated regarding pathology that was not visible in the image/video clips provided.

Thank you for this referral. If the clinical or image interpretation does not parallel your findings or if I can be of any further assistance please contact me.

Sebastian Schaub, Sebastian Schaub, DVM, Dr. med. vet. DipECVDI
sebast.schaub@gmail.com