

**PATIENT**

Carmella Fontana

**PRESENTING CLINICAL SIGNS**

\* episodes of diarrhea in 24 hours, 1 episode of vomiting.

**SPECIES**

Canine

**RADIOGRAPHIC STUDY OF THE ABDOMEN**

Radiographs of the abdomen in three imaging planes are provided for review.

**BREED**

Bichon Poo

The patient presents with a lean body condition.

The surrounding bony structures are within normal limits.

**SEX**

FS

No abnormalities of the extraabdominal soft tissues are noted. The abdominal wall is smooth and thin.

The serosal detail is maintained throughout the peritoneal and retroperitoneal space. Two metal opaque surgical clips are seen in the caudal abdomen.

**AGE**

1.5 Years

The liver is appropriate in position, size and presents uniform opacity.

The splenic head is in the anticipated position and within normal limits for size and opacity. The splenic body and tail are considered normal for position, size, shape and opacity.

**INTERPRETED BY**

Sebastian Schaub, DVM  
Dr. med. vet. DipECVDI

Both kidneys are seen and present with normal size, shape, delineation and opacity. The urinary bladder is empty and not appreciated.

The stomach is in its anticipated position and is empty.

**HOSPITAL NAME**

Four Corners  
Veterinary Practice

The small intestinal loops are of even diameter and non-dilated, a small amount of gas is seen within the small intestinal loops and considered within normal limits.

The colon is seen in the expected position and contains a mild amount of gas.

**REFERRING VET**

Gregory Roccaro

- Empty gastrointestinal tract

**RADIOGRAPHIC DIAGNOSIS****INTERPRETATION OF THE FINDINGS & FURTHER RECOMMENDATIONS****INVOICE**

49316

There is no evidence of radiopaque foreign material or signs for gastrointestinal mechanical obstruction and the presumptive diagnosis is gastroenteritis. If clinical signs are refractory to therapy, recommend follow up radiographs or a complete abdominal ultrasound examination; in some cases, a high ileus may lack classical radiographic signs of mechanical obstruction.

**DATE**

12-29-21



**PATIENT**

Carmella Fontana

**SPECIES**

Canine

**BREED**

Bichon Poo

**SEX**

FS

**AGE**

1.5 Years

**INTERPRETED BY**

Sebastian Schaub, DVM  
Dr. med. vet. DipECVDI

**HOSPITAL NAME**

Four Corners  
Veterinary Practice

**REFERRING VET**

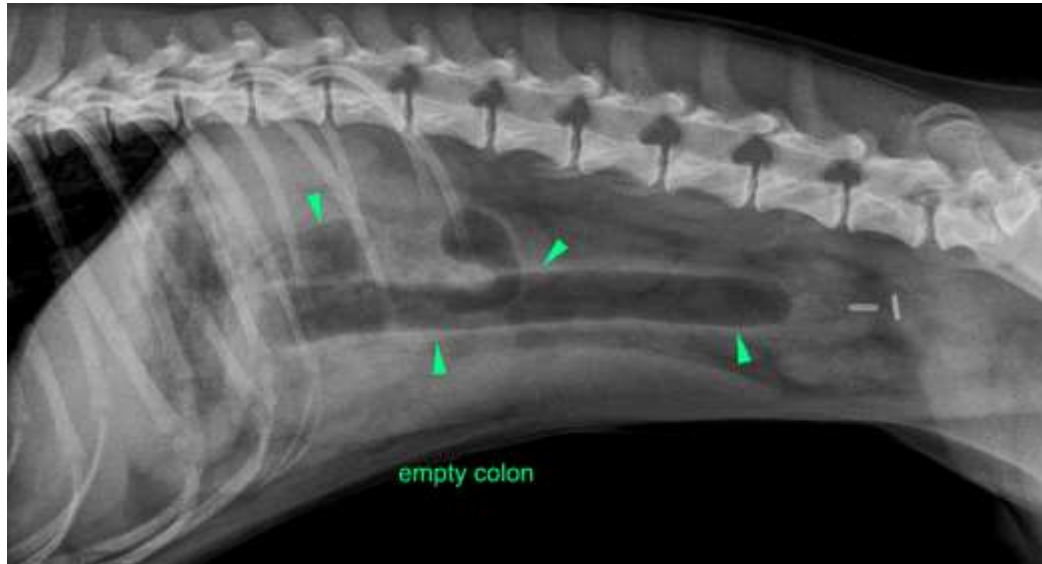
Gregory Roccaro

**INVOICE**

49316

**DATE**

12-29-21



The information and recommendations provided are based on the images presented by the referring veterinarian. No evaluation can be communicated regarding pathology that was not visible in the image/video clips provided.

Thank you for this referral. If the clinical or image interpretation does not parallel your findings or if I can be of any further assistance please contact me.

**Sebastian Schaub**, Sebastian Schaub, DVM, Dr. med. vet. DipECVDI  
sebast.schaub@gmail.com