



PATIENT PRESENTING CLINICAL SIGNS

Lucy Purcell ataxic...lethargic
Abnormal PE/Chem/CBC/UA Results: Pending

SPECIES RADIOGRAPHIC STUDY OF THE THORAX & ABDOMEN

Feline An overview study including the thorax and abdomen in a lateral projection is provided for review.

BREED RADIOGRAPHIC FINDINGS

Domestic Shorthair Thorax

The surrounding bony structures are within normal limits.

SEX The extrathoracic soft tissues present homogeneous without abnormalities.

Female/sp The heart is of normal size and shape, there is no evidence of cardiac chamber or vascular enlargement. The pulmonary vasculature is within normal limits.

AGE The trachea is normal in diameter and presents the anticipated course. The luminal outline of the trachea is smooth.

16 Years

INTERPRETED BY In the caudoventral lung field and the perihilar region, areas of granulated mineralization of the lung parenchyma are seen. The remainder of the lung parenchyma are aerated and present the expected architecture; the pulmonary vasculature can be appreciated up into the periphery of the lung.

Sebastian Schaub, DVM
Dr. med. vet. DipECVDI

HOSPITAL NAME The diaphragm is well delineated with even surface and the expected mild cranial bulging of the diaphragmatic cupola.

New Bridge Veterinary Practice Abdomen

A small osseous spur is emanating from the proximal margin of one the ischial bone.

REFERRING VET No abnormalities of the extraabdominal soft tissues are noted. The abdominal wall is smooth and thin.

Dr. Abina Glennon

The serosal detail is maintained throughout the peritoneal and retroperitoneal space.

INVOICE The hepatic volume is mildly increased and the caudoventral margins of the liver are rounded.

49269 Both kidneys are seen and present with normal size, shape, delineation and opacity. The urinary bladder is in its anticipated position. No radiopaque calculi are noted throughout the upper and lower urinary tract.

DATE The stomach is in its anticipated position and presents normal content.

12-27-21 The small intestinal loops are of even diameter and non-dilated, a small amount of gas is seen within the small intestinal loops and considered within normal limits.



PATIENT

Lucy Purcell

The colon is seen in the expected position and presents with appropriate content.

RADIOGRAPHIC DIAGNOSIS

SPECIES

Feline

- Areas of granular mineralization of the lung parenchyma, otherwise normal lung
- Mild hepatomegaly
- Small exostosis ischial bone (unknown side), incidental

INTERPRETATION OF THE FINDINGS & FURTHER RECOMMENDATIONS

BREED

Domestic Shorthair

The mineralization of the lung field is most consistent with broncholithiasis, likely as a sequela to feline bronchial disease. The broncholithiasis is suspected to be due to mineralization of secretions in the bronchial lumen. Although neoplastic transformation is still a consideration – such as bronchogenic carcinoma – I considered the odds low and the mineralization likely are an incidental finding at this point.

SEX

Female/sp

Potentials for the hepatomegaly include metabolic hepatic disease/steroid induced hepatopathy, hepatitis or neoplastic infiltration. Ultrasound including FNA sampling can be used as minimally advanced diagnostic tests.

AGE

16 Years

No abnormalities are appreciated, explaining the ataxia.

INTERPRETED BY

Sebastian Schaub, DVM
Dr. med. vet. DipECVDI

HOSPITAL NAME

New Bridge
Veterinary Practice

REFERRING VET

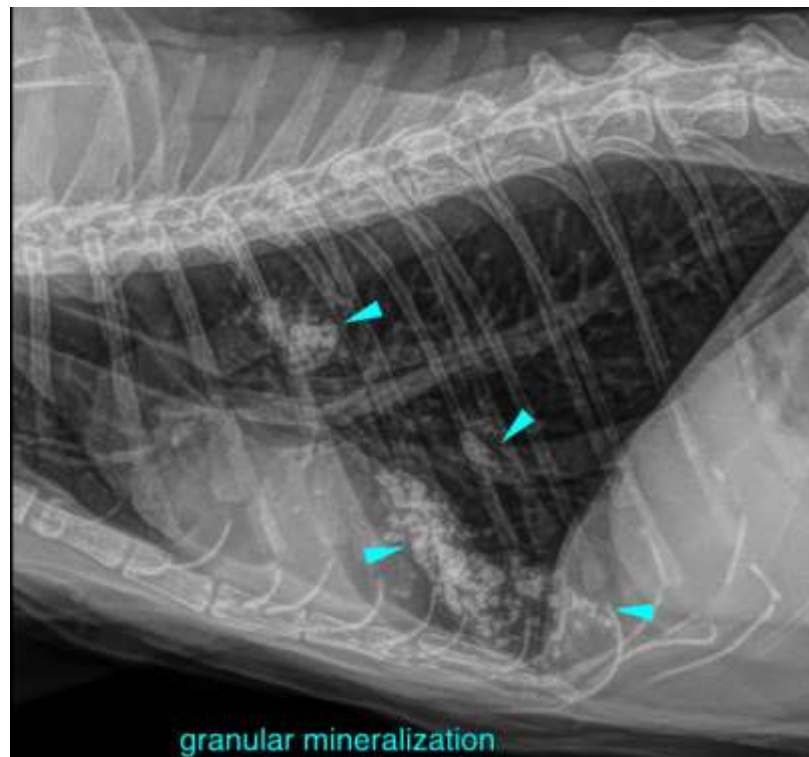
Dr. Abina Glennon

INVOICE

49269

DATE

12-27-21





PATIENT

Lucy Purcell

SPECIES

Feline

BREED

Domestic Shorthair

SEX

Female/sp

AGE

16 Years

INTERPRETED BY

Sebastian Schaub, DVM
Dr. med. vet. DipECVDI

HOSPITAL NAME

New Bridge
Veterinary Practice

REFERRING VET

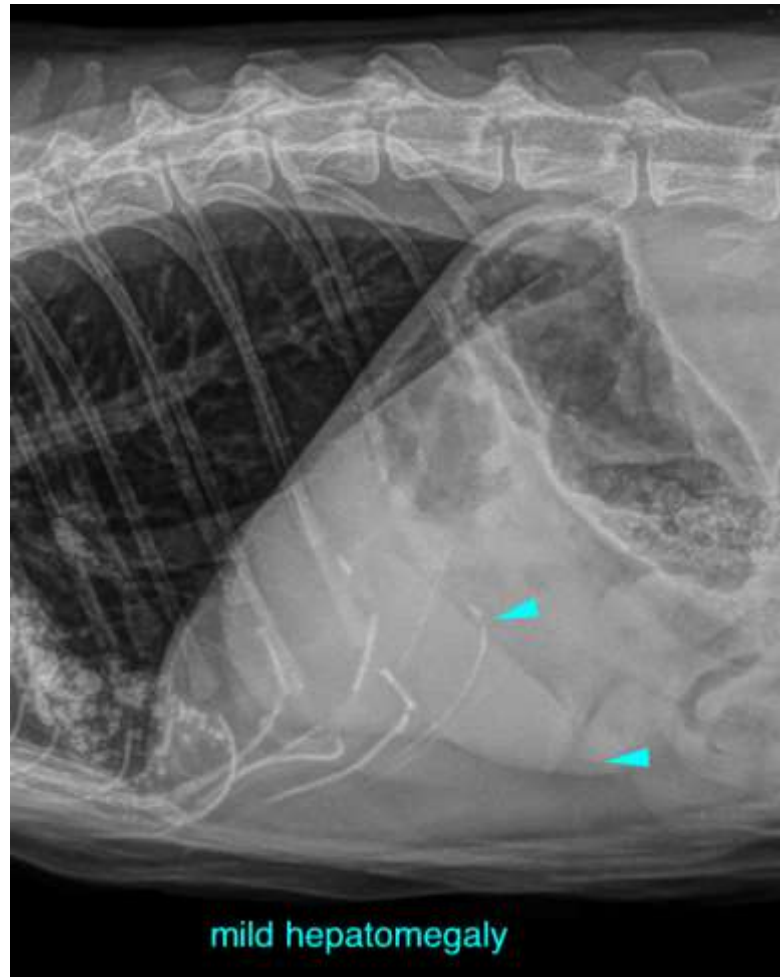
Dr. Abina Glennon

INVOICE

49269

DATE

12-27-21



The information and recommendations provided are based on the images presented by the referring veterinarian. No evaluation can be communicated regarding pathology that was not visible in the image/video clips provided.

Thank you for this referral. If the clinical or image interpretation does not parallel your findings or if I can be of any further assistance please contact me.

Sebastian Schaub, Sebastian Schaub, DVM, Dr. med. vet. DipECVDI
sebast.schaub@gmail.com