



PATIENT PRESENTING CLINICAL SIGNS

PATIENT Shyla Crooks
SPECIES Canine
BREED Pitbull Terrier

Had a splenectomy with single bleeding mass on 12/19 at Wilvet Salem. Prior to surgery had some degree of azotemia. Re-presented 12/23 morning for poor appetite, painful mouth and inability for owners to give medications. Also had some left sided facial swelling. Owner has been having a hard time getting her medications into her as well as she will spit out the tablets. 12/23 day Dr. Peterson suspected retrobulbar abscess, sedated and tried needle aspirate in the back of the left side of the mouth minimal amount of material obtained.

Abnormal PE/Chem/CBC/UA Results: 12/23 AFAST - no free fluid noted, mesentery appears hyperechoic Fluorescein stain - no uptake noted PCV/TS - 38%, 7.0 g/dL CBC - Regenerative Anemia HCT 31.5%, Retics 147.2, Marked leukocytosis 36.7k, Neutrophilia 31.2, Monocytosis 2.93k, Chem10 - Azotemia CREA 2.1 (static), BUN 25, rest wnl 12/24: EPOC: HCT 27 Creat 1.42 BUN 29 pH 7.348 PCV/TS: 30/6.6

COMPUTED TOMOGRAPHY OF THE SKULL

SEX A high resolution pre- and post-contrast CT study of the skull is provided for review.

FS **COMPUTED TOMOGRAPHIC FINDINGS**

The pictured parts of the dentition are complete and unremarkable in all jaw quadrants.

AGE A moderate subcutaneous swelling is seen in the left buccal region.

9 In the ventral aspect of the left orbit, a peripheral contrast enhancing and central hypoattenuating roundish lesion is appreciated, measuring 3.5 x 3.3 x 2.6 cm in size. The left ocular bulb is deviated dorsally and rostrally by the mass effect.

INTERPRETED BY

Sebastian Schaub, DVM
 Dr. med. vet. DipECVDI

The nasal cavity presents the expected aerated spaces between thin & even conchae and turbinates with smooth mucosal lining – a nasoesophageal tube is appreciated.

HOSPITAL NAME

Wilvet Salem

Both temporomandibular joints present congruent joint spaces with even subchondral bone surfaces and are considered within normal limits.

Both tympanic bullae are aerated, the mucosal lining is not seen, the bony wall is smooth and thin. The external ear canals are within normal limits.

REFERRING VET

Dr. Gardner

The brain presents no deviation from normal anatomy and symmetry. The brain parenchyma is homogeneous and within normal limits for attenuation and distribution of contrast enhancement. The ventricular system is non-dilated and symmetric.

The left mandibular lymph nodes are mildly prominent.

INVOICE

55834

COMPUTED TOMOGRAPHIC DIAGNOSIS

- Left sided cavitory lesion ventral aspect of the orbit
- Edematous swelling left buccal region
- Left sided mild exophthalmos
- Mild lymphadenopathy left mandibular lymph nodes

DATE

12-26-22

INTERPRETATION OF THE FINDINGS & FURTHER RECOMMENDATIONS

The left sided cavitory retrobulbar lesion in combination with the laboratory changes and the edematous swelling along the left buccal region is supporting the diagnosis of retrobulbar abscess formation – e.g. preceding perforating trauma, migrating foreign body (no foreign



PATIENT

Shyla Crooks

material is appreciated in the current CT study). As the mass appears to be confluent with the left zygomatic gland, sialocele of the left zygomatic gland or far less likely cystic neoplasia are differentials. If cytology of the retrobulbar aspirate reveals inflammatory changes, surgical drainage of the abscess is recommended.

SPECIES

Canine

BREED

Pitbull Terrier

SEX

FS

AGE

9

INTERPRETED BY

Sebastian Schaub, DVM
Dr. med. vet. DipECVDI

HOSPITAL NAME

Wilvet Salem

REFERRING VET

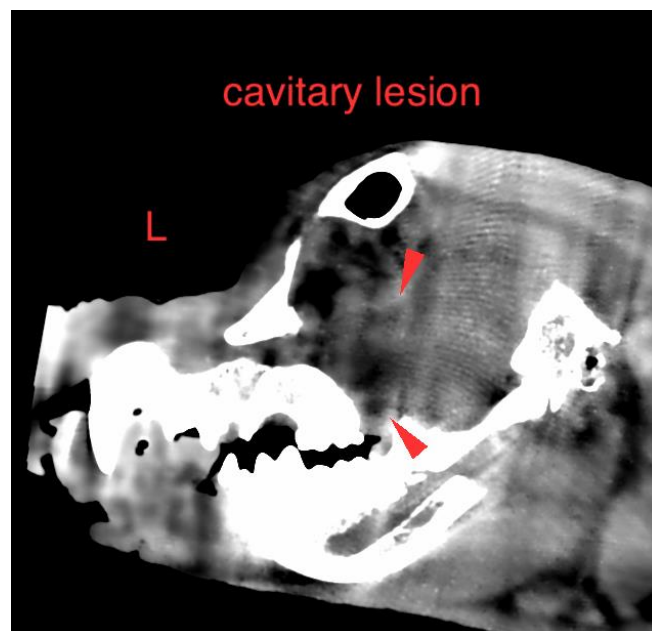
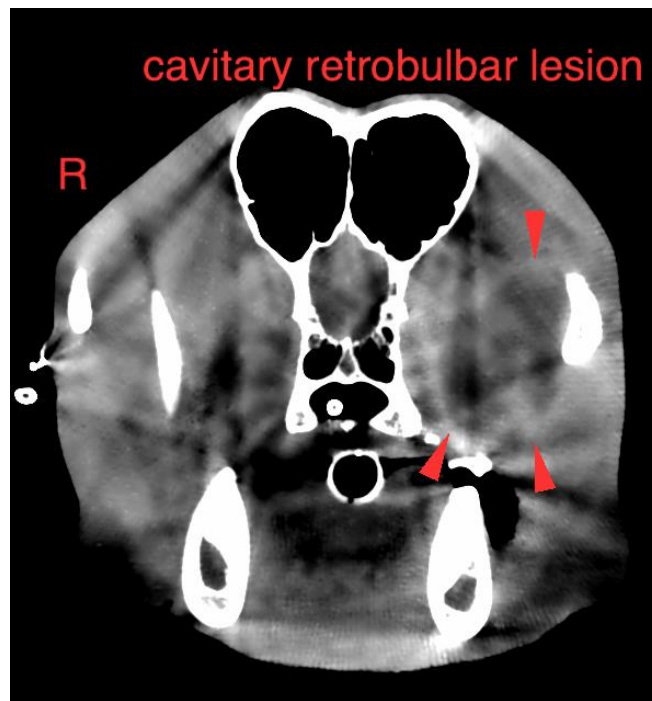
Dr. Gardner

INVOICE

55834

DATE

12-26-22





PATIENT

Shyla Crooks

The information and recommendations provided are based on the images presented by the referring veterinarian/sonographer. No evaluation can be communicated regarding pathology that was not visible in the image/video clips provided.

SPECIES

Canine

Thank you for this referral. If the clinical or image interpretation does not parallel your findings or if I can be of any further assistance please contact me.

BREED

Pitbull Terrier

Sebastian Schaub, Sebastian Schaub, DVM, Dr. med. vet. DipECVDI
sebast.schaub@gmail.com

SEX

FS

AGE

9

INTERPRETED BY

Sebastian Schaub, DVM
Dr. med. vet. DipECVDI

HOSPITAL NAME

Wilvet Salem

REFERRING VET

Dr. Gardner

INVOICE

55834

DATE

12-26-22