



**PATIENT**

Loki Mueller

**PRESENTING CLINICAL SIGNS**

Several month history of LTL lameness, no improvement with NSAID and exercise restriction. Radiographs reviewed by radiologist were unremarkable. Unrelated "fly biting" behavior. Abnormal PE/Chem/CBC/UA Results: Difficult to localize lameness

**SPECIES**

Canine

**COMPUTED TOMOGRAPHY OF THE LEFT FRONT LIMB**

A high resolution pre- and post-contrast CT study of the left front limb is provided for review.

**BREED**

Mixed Breed

**COMPUTED TOMOGRAPHIC FINDINGS**

There is image mislabeling due to wrong patient positioning setting and R is indicating the left side of the patient and vice versa.

The osseous and surrounding soft tissue structures of the left shoulder joint present without abnormalities.

**SEX**

MN

The periarticular bones of the left elbow joint present moderate osteophyte new bone formation. The medial coronoid process is shallow and at the cranial aspect an isolated, mineral attenuating body is visible, measuring 6.0 x 4.6 x 6.6 mm in size. The subchondral bone opposing the medial coronoid process of the humeral condyle presents a small crescent shaped defect with surrounding moderate sclerosis. Post contrast administration, the joint capsule of the left elbow joint is prominent.

**AGE**

11 Months

**COMPUTED TOMOGRAPHIC DIAGNOSIS**

- Fragmented medial coronoid process (FCP) left elbow joint
- Degenerative osteoarthritis left elbow joint
- Suspect small 'kissing lesion' medial aspect left humeral condyle
- Synovialitis left elbow joint

**INTERPRETED BY**

Sebastian Schaub, DVM  
Dr. med. vet. DipECVDI

**HOSPITAL NAME**

Healing Spirit Animal  
Wellness

**INTERPRETATION OF THE FINDINGS & FURTHER RECOMMENDATIONS**

The findings are consistent with mild to moderate chronic degenerative joint disease of the left elbow joint due to a fragmented medial coronoid process.

Arthroscopy is recommended to revise the elbow joint and remove the fragment of the medial coronoid process and prevent further damage.

**REFERRING VET**

Desen Ertunc, DVM

**INVOICE**

55838

**DATE**

12-26-22



**PATIENT**

Loki Mueller

**SPECIES**

Canine

**BREED**

Mixed Breed

**SEX**

MN

**AGE**

11 Months

**INTERPRETED BY**

Sebastian Schaub, DVM  
Dr. med. vet. DipECVDI

**HOSPITAL NAME**

Healing Spirit Animal  
Wellness

**REFERRING VET**

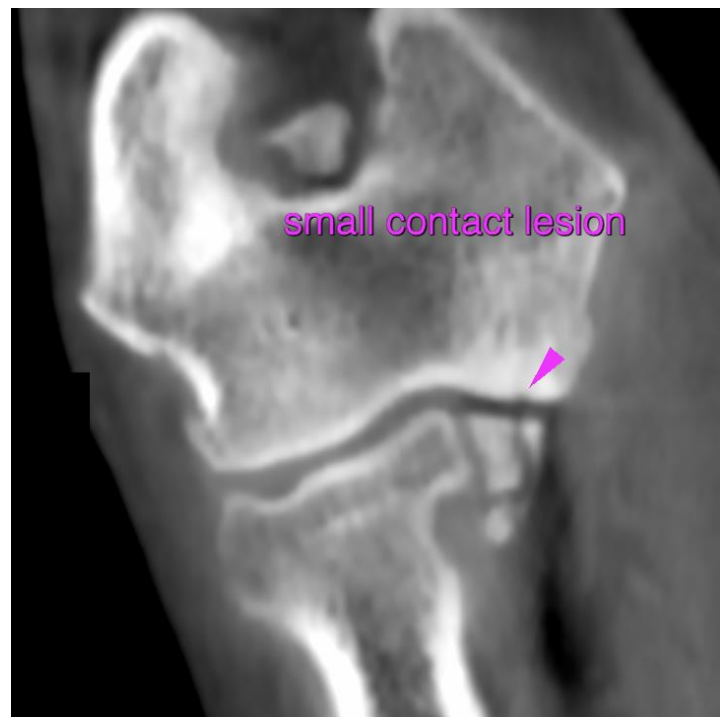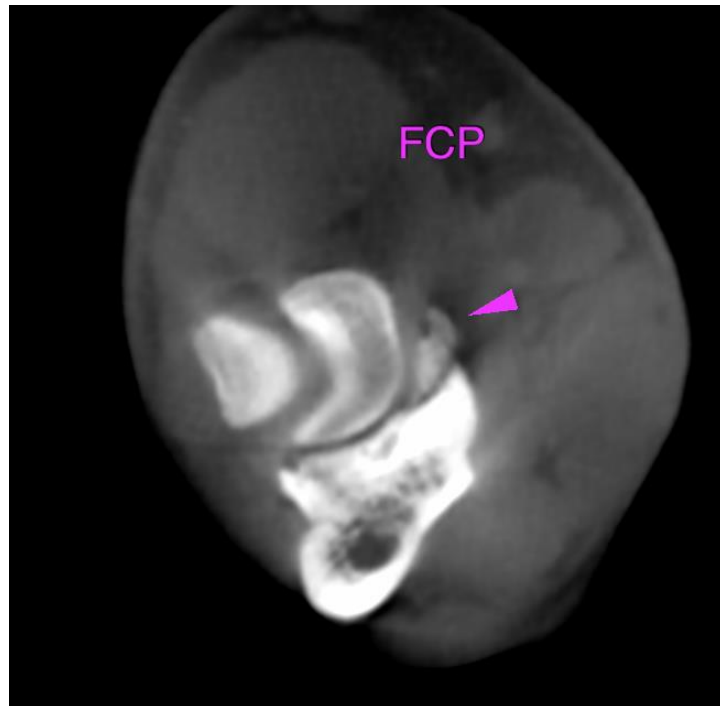
Desen Ertunc, DVM

**INVOICE**

55838

**DATE**

12-26-22





**PATIENT**

Loki Mueller

The information and recommendations provided are based on the images presented by the referring veterinarian/sonographer. No evaluation can be communicated regarding pathology that was not visible in the image/video clips provided.

**SPECIES**

Canine

Thank you for this referral. If the clinical or image interpretation does not parallel your findings or if I can be of any further assistance please contact me.

**Sebastian Schaub**, Sebastian Schaub, DVM, Dr. med. vet. DipECVDI  
sebast.schaub@gmail.com

**BREED**

Mixed Breed

**SEX**

MN

**AGE**

11 Months

**INTERPRETED BY**

Sebastian Schaub, DVM  
Dr. med. vet. DipECVDI

**HOSPITAL NAME**

Healing Spirit Animal  
Wellness

**REFERRING VET**

Desen Ertunc, DVM

**INVOICE**

55838

**DATE**

12-26-22