



PATIENT

Angus Alves

SPECIES

Canine

BREED

West Highland Terrier

SEX

Neutered Male

AGE

16 Years

WEIGHT

25.8 lbs

INTERPRETED BY

Sebastian Schaub, DVM
Dr. med. vet. DipECVDI

IMAGING PERFORMED BY

Mobile Pet Imaging

HOSPITAL NAME

Mobile Pet Imaging

REFERRING VET

Dr. Armstrong

INVOICE

72757

DATE

12/24/25

PRESENTING CLINICAL SIGNS

Presented for recheck cough. Owner noted he improved initially on treatment for suspected collapsing trachea 2-3 weeks ago. Pet was on antibiotics, cough tabs and hydrocodone. When completed, he started coughing again.

COMPUTED TOMOGRAPHIC STUDY OF THE THORAX

A high resolution pre- and post-contrast CT study of the thorax is provided for review.

COMPUTED TOMOGRAPHIC FINDINGS

The bony and surrounding soft tissue structures are within normal limits.

The sternal, cranial mediastinal and tracheobronchial lymph nodes are small elongated with a normal short-to-long-axis-ratio is < 0.5 , the attenuation and contrast enhancement pattern is uniform and considered within normal limits.

The cardiovascular structures including the pulmonary vasculature are within normal limits.

Moderate dorsoventral flattening of the trachea is appreciated.

In the cranioventral aspect of the left caudal lung lobe is consolidated and presents a mild heterogenous contrast enhancement pattern; the associated bronchi are compressed. The consolidated area of the left caudal lung lobe is measuring approximately 6.0 x 3.3 x 5.1 cm. Generalized significant thickening of the walls of the bronchial tree is appreciated.

Small incidental gas pockets are seen within the esophageal lumen, there is no evidence of abnormal dilation.

COMPUTED TOMOGRAPHIC DIAGNOSIS

- Soft tissue mass left caudal lung lobe
- Generalized significant thickening of the bronchial walls
- Tracheal collapse

INTERPRETATION OF THE FINDINGS & FURTHER RECOMMENDATIONS

The pulmonary changes are highly suggestive for underlying primary pulmonary soft tissue neoplasia with neoplastic infiltration of the walls of the bronchial tree – bronchogenic carcinoma is the top differentia. Theoretically an inflammatory origin such as eosinophilic granulomatosis is a potential, but the odds are low. FNA sampling of the pulmonary mass ± bronchoscopy including BAL can be used as advanced diagnostic tools.



PATIENT

Angus Alves

SPECIES

Canine

BREED

West Highland Terrier

SEX

Neutered Male

AGE

16 Years

WEIGHT

25.8 lbs

INTERPRETED BY

Sebastian Schaub, DVM
Dr. med. vet. DipECVDI

IMAGING PERFORMED BY

Mobile Pet Imaging

HOSPITAL NAME

Mobile Pet Imaging

REFERRING VET

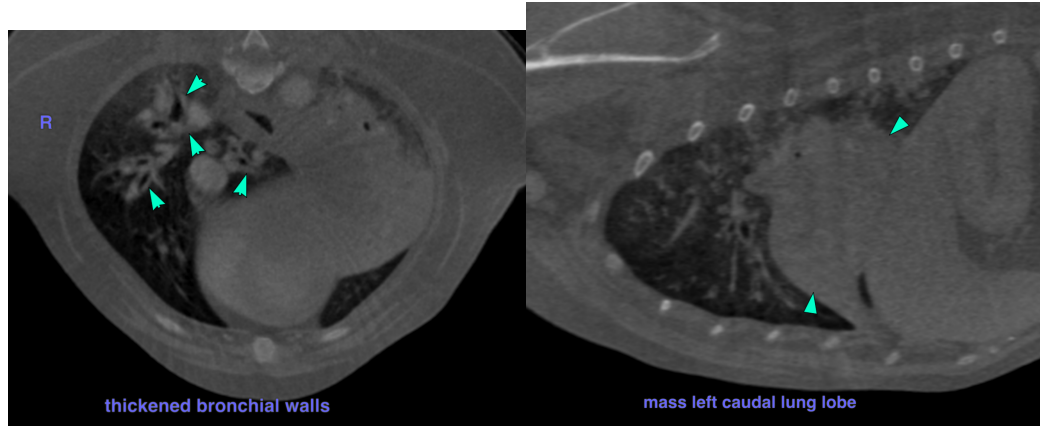
Dr. Armstrong

INVOICE

72757

DATE

12/24/25



The information and recommendations provided are based on the images presented by the referring veterinarian/sonographer. No evaluation can be communicated regarding pathology that was not visible in the image/video clips provided.

Thank you for this referral. If the clinical or image interpretation does not parallel your findings or if I can be of any further assistance please contact me.

Sebastian Schaub, DVM, Dr. med. vet. DipECVDI
info@sonopath.com