



**PATIENT**

Ms Minette Tremblay

**PRESENTING CLINICAL SIGNS**

Reason for Visit: LIMPING RIGHT HIND History: 3YR OLD SPAYED DSH PRESENTED FOR LIMPING IN THE RIGHT HIND LEG. PET FELL OF 5TH FLOOR BALCONY LAST EVENING(DID NOT SEE IT HAPPEN). OWNER WAS IN ROOM WITH PET ALL NIGHT, HASN'T USED LITTERBOX OR HAD FOOD. OTHER THAN LIMPING, OUTWARDLY SHE LOOKS FINE. Abnormal PE/Chem/CBC/UA Results: CV/Respiratory: Normal heart rate and rhythm, no murmur, pulses strong and synchronous, normal bronchovesicular sounds. EENT: Clear OU and AU. No nasal discharge. No cough on tracheal palpation. Oral cavity: Mild dental tartar Musculoskeletal: BCS = 6/9. Ambulatory x 4. RH: grade 5/5 lameness, very painful at proximal femur and coxofemoral joint on palpation Uro/Perineum: No significant lesions Abd/GI: Soft, non-painful. No masses or fluid wave palpated Lymph Nodes: No peripheral lymphadenopathy Neurological: Alert and appropriate. No significant abnormalities Skin: Good hair coat. No ectoparasites seen Mentation: BAR Hydration: N

**SPECIES**

Feline

**BREED**

DSH

**SEX**

SF

**RADIOGRAPHIC STUDY OF THE PELVIS**

Radiographs of the pelvis in two orthogonal imaging planes are provided for review.

**RADIOGRAPHIC FINDINGS**

The osseous structures of the pelvis are within normal limits. The coxofemoral joints present smooth osseous margins.

A small gas opacity is superimposed on the soft tissues lateral aspect of the right.

**RADIOGRAPHIC DIAGNOSIS**

- Normal pelvis/coxofemoral joints
- Small gas inclusion right thigh

**INTERPRETATION OF THE FINDINGS & FURTHER RECOMMENDATIONS**

No abnormalities of the osseous structures of the pelvis and coxofemoral joints are appreciated. If clinical signs are refractory to empirical therapy by rest and pain-management, distracted radiographs of the coxofemoral joints can be used to rule out fractured femoral head – that might be not appreciated in the current radiographic study.

The small gas inclusion can be a sequela to preceding injection; rule out perforating wound.

**INTERPRETED BY**

Sebastian Schaub, DVM  
Dr. med. vet. DipECVDI

**HOSPITAL NAME**

DPC Veterinary  
Hospital

**REFERRING VET**

Dr. Rivera

**INVOICE**

49234

**DATE**

12-24-21



**PATIENT**

Ms Minette Tremblay

**SPECIES**

Feline

**BREED**

DSH

**SEX**

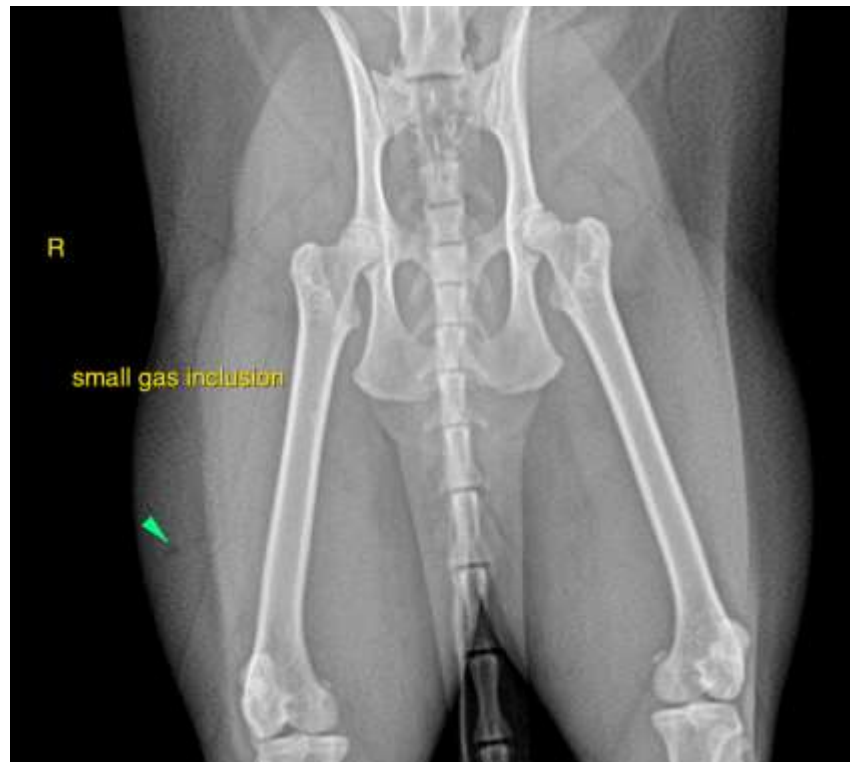
SF

**AGE**

3 Years, 2 Months

**INTERPRETED BY**

Sebastian Schaub, DVM  
Dr. med. vet. DipECVDI



**HOSPITAL NAME**

DPC Veterinary  
Hospital

**REFERRING VET**

Dr. Rivera

**INVOICE**

49234

**DATE**

12-24-21

The information and recommendations provided are based on the images presented by the referring veterinarian. No evaluation can be communicated regarding pathology that was not visible in the image/video clips provided.

Thank you for this referral. If the clinical or image interpretation does not parallel your findings or if I can be of any further assistance please contact me.

**Sebastian Schaub**, Sebastian Schaub, DVM, Dr. med. vet. DipECVDI  
sebast.schaub@gmail.com