



PATIENT

Fred Bowler

SPECIES

Canine

BREED

Chow/Mix

SEX

MN

AGE

12Y

WEIGHT

89.6

INTERPRETED BY

Sebastian Schaub, DVM
Dr. med. vet.
DipECVDI

IMAGING PERFORMED BY

Alec

HOSPITAL NAME

Ramapo Valley Animal
Hospital

REFERRING VET

Dr. Katara

INVOICE

73110

DATE

12-23-25

PRESENTING CLINICAL SIGNS

Pre-op chest xrays. Mass in mouth. Scheduled for mass removal. D.r Katara wants to rule out mass in chest vs metastatic lesion. Second opinion on xrays

RADIOGRAPHIC STUDY OF THE THORAX

Radiographs of the thorax in three imaging planes are provided for review.

RADIOGRAPHIC FINDINGS

Along the thoracic spine, multifocal spondylosis formation is seen.

The extrathoracic soft tissues present homogeneous without abnormalities.

The heart is of normal size and shape; there is no evidence of cardiac chamber or vascular enlargement. The pulmonary vasculature is within normal limits.

The cranial mediastinum presents the expected soft tissue opacity. The mediastinal width is less than twice the width of the vertebral column at the same level.

The trachea is normal in diameter and presents the anticipated course. The luminal outline of the trachea is smooth.

The bronchial tree presents with thin walls and tapers uniformly towards the periphery as expected.

The lung parenchyma presents the expected architecture and ground glass opacity; the intrapulmonary vascular branching is seen up to the third order lung vessels.

The diaphragm is well delineated with even surface and the expected mild cranial bulging of the diaphragmatic cupola.

RADIOGRAPHIC DIAGNOSIS

- Generalized increased radiopacity of the lung field – considered as a sequela to the nutritional status
- Spondylosis deformans

INTERPRETATION OF THE FINDINGS & FURTHER RECOMMENDATIONS

I consider the esophagus to be negative for pulmonary metastatic disease and the generalized increased radiopacity is a sequela to the nutritional status, accentuated by hypoinflation and age related changes of the lung.



PATIENT

Fred Bowler

SPECIES

Canine

BREED

Chow/Mix

SEX

MN

AGE

12Y

WEIGHT

89.6

INTERPRETED BY

Sebastian Schaub, DVM
Dr. med. vet.
DipECVDI

IMAGING PERFORMED BY

Alec

HOSPITAL NAME

Ramapo Valley Animal
Hospital

REFERRING VET

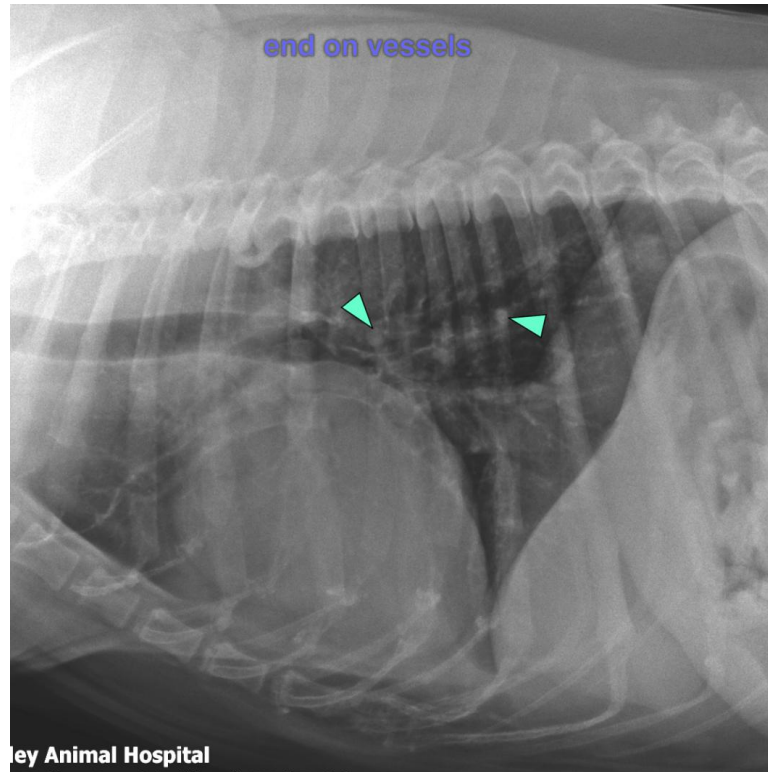
Dr. Katara

INVOICE

73110

DATE

12-23-25



The information and recommendations provided are based on the images presented by the referring veterinarian/sonographer. No evaluation can be communicated regarding pathology that was not visible in the image/video clips provided.

Thank you for this referral. If the clinical or image interpretation does not parallel your findings or if I can be of any further assistance please contact me.

Sebastian Schaub, Sebastian Schaub, DVM, Dr. med. vet. DipECVDI
info@sonopath.com