



PATIENT

Scout Gardner

PRESENTING CLINICAL SIGNS

Chronic R forelimb lameness (for past 10 months). CT scan sent to Sonopath from Oct 2022, no abnormalities found in R Forelimb. Submitting R forelimb MRI for further investigation into lameness

SPECIES

Canine

MAGNETIC RESONANCE IMAGING OF THE RIGHT SHOULDER JOINT

T2, PD and T1 weighted pre- and post-gadolinium sequence in multiple imaging planes are provided for review.

BREED

Labrador X

MAGNETIC RESONANCE IMAGING FINDINGS

The right shoulder joint presents a mild intracapsular swelling. The bicipital tendon has a mild heterogeneous hyperintense signal and the mid segment presents mild feathered margins.

SEX

FS

The remainder of the osseous and soft tissue structures of the right shoulder joint are within normal limits. The pictured parts of the brachial plexus are unremarkable.

AGE

9 Years

MAGNETIC RESONANCE IMAGING DIAGNOSIS

- Tendinopathy right bicipital tendon with mild fibrillation and possible mild fibrous adhesions with the tendon sheath
- Mild effusion right shoulder joint

INTERPRETED BY

Sebastian Schaub, DVM
Dr. med. vet. DipECVDI

INTERPRETATION OF THE FINDINGS & FURTHER RECOMMENDATIONS

There is evidence of mild tendinopathy with potential mild fibrillation of the right bicipital tendon. Check clinically if pain can be elicited by pressure on the bicipital tendon. Diagnostic therapy by intraarticular injection of glucocorticoid administration into the right shoulder joint might be tried.

HOSPITAL NAME

Animal Health
Partners

REFERRING VET

Dr. Lea Mehrkens

INVOICE

55911

DATE

12-23-22



PATIENT

Scout Gardner

SPECIES

Canine

BREED

Labrador X

SEX

FS

AGE

9 Years

INTERPRETED BY

Sebastian Schaub, DVM
Dr. med. vet. DipECVDI

HOSPITAL NAME

Animal Health
Partners

REFERRING VET

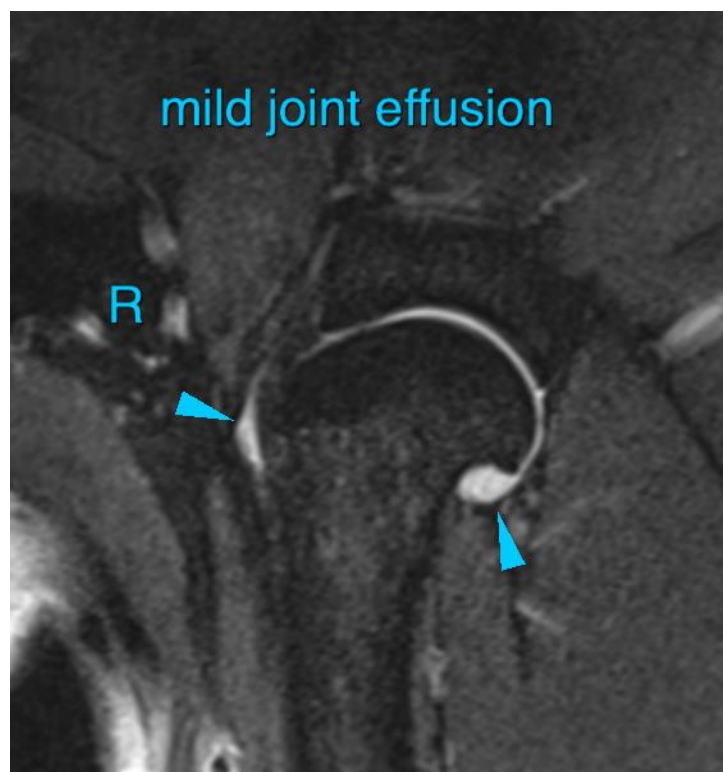
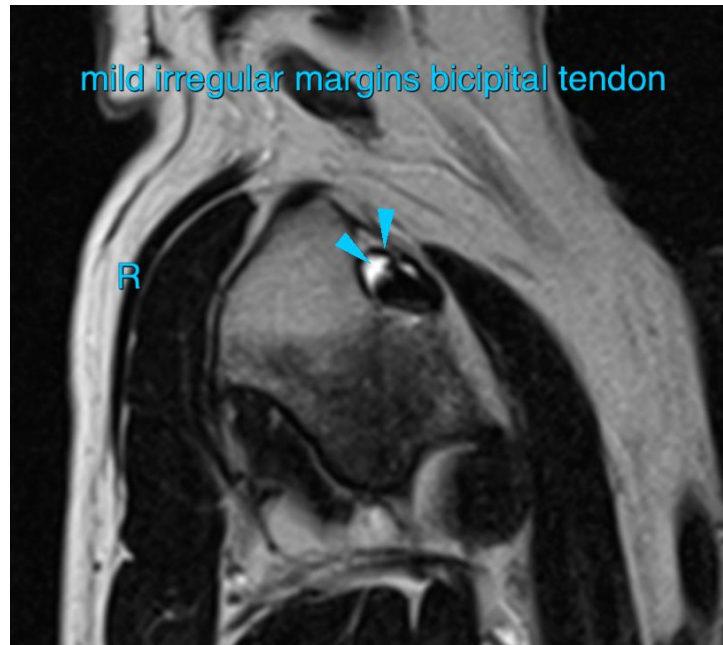Dr. Lea Mehrkens

INVOICE

55911

DATE

12-23-22





PATIENT

Scout Gardner

The information and recommendations provided are based on the images presented by the referring veterinarian/sonographer. No evaluation can be communicated regarding pathology that was not visible in the image/video clips provided.

SPECIES

Canine

Thank you for this referral. If the clinical or image interpretation does not parallel your findings or if I can be of any further assistance please contact me.

Sebastian Schaub, Sebastian Schaub, DVM, Dr. med. vet. DipECVDI
sebast.schaub@gmail.com

BREED

Labrador X

SEX

FS

AGE

9 Years

INTERPRETED BY

Sebastian Schaub, DVM
Dr. med. vet. DipECVDI

HOSPITAL NAME

Animal Health
Partners

REFERRING VET

Dr. Lea Mehrkens

INVOICE

55911

DATE

12-23-22