



PATIENT PRESENTING CLINICAL SIGNS

Elly Bingham Noticed lump on R shoulder 3 months ago. It started off small then grew significantly. Got biopsy sample on 12/9/22. It came back as a fibrosarcoma. Highly aggressive. O wants to pursue surgical removal.

SPECIES Abnormal PE/Chem/CBC/UA Results: Grade 2/6 heart murmur

Feline **COMPUTED TOMOGRAPHY OF THE NECK/THORAX**

A high resolution pre- and post-contrast CT study of the neck is provided for review.

BREED COMPUTED TOMOGRAPHIC FINDINGS

DSH Extending from the cranioproximal margin of the right scapula along the right dorsolateral aspect of the right thoracic wall up to the level of T8, a uniform soft tissue attenuating and heterogeneous contrast enhancing mass is seen. The mass is ill-defined in the medial aspect and extending into the subscapular region and is in close contact with the musculature of the right scapula and the epaxial musculature. The mass is measuring 6.1 x 6.2 x 9.8 cm in size. In the dorsomedial aspect, the mass is partially crossing the midline.

SEX The right superficial cervical lymph node is prominent, uniform soft tissue attenuating and homogeneous contrast enhancing.

Female Spayed

AGE The lung parenchyma presents multiple regions with dystelectasis

4 Years

COMPUTED TOMOGRAPHIC DIAGNOSIS

INTERPRETED BY

- Large invasive growing cavitary soft tissue mass along the right scapula and dorsolateral thoracic wall
- Lymphadenopathy right superficial cervical lymph node
- No sign for pulmonary metastatic disease

Sebastian Schaub, DVM
Dr. med. vet. DipECVDI

HOSPITAL NAME

INTERPRETATION OF THE FINDINGS & FURTHER RECOMMENDATIONS

Parrish Creek
Veterinary Clinic

The soft tissue mass is fitting the history of fibrosarcoma, the mass presents signs for local invasive growth/is confluent with the right scapular and epaxial musculature along the thoracic spine. Unfortunately, complete surgical excision of the mass is considered not feasible as clean margins along the spine will not be achieved. However, if surgery is still an option amputation of the right front limb is warranted and adjuvant treatment options should be discussed with oncologist.

REFERRING VET

The odds for metastatic disease to the right superficial lymph node are high.

Jennifer Shuck, DVM

INVOICE

55805

DATE

12-23-22



PATIENT

Elly Bingham

SPECIES

Feline

BREED

DSH

SEX

Female Spayed

AGE

4 Years

INTERPRETED BY

Sebastian Schaub, DVM
Dr. med. vet. DipECVDI

HOSPITAL NAME

Parrish Creek
Veterinary Clinic

REFERRING VET

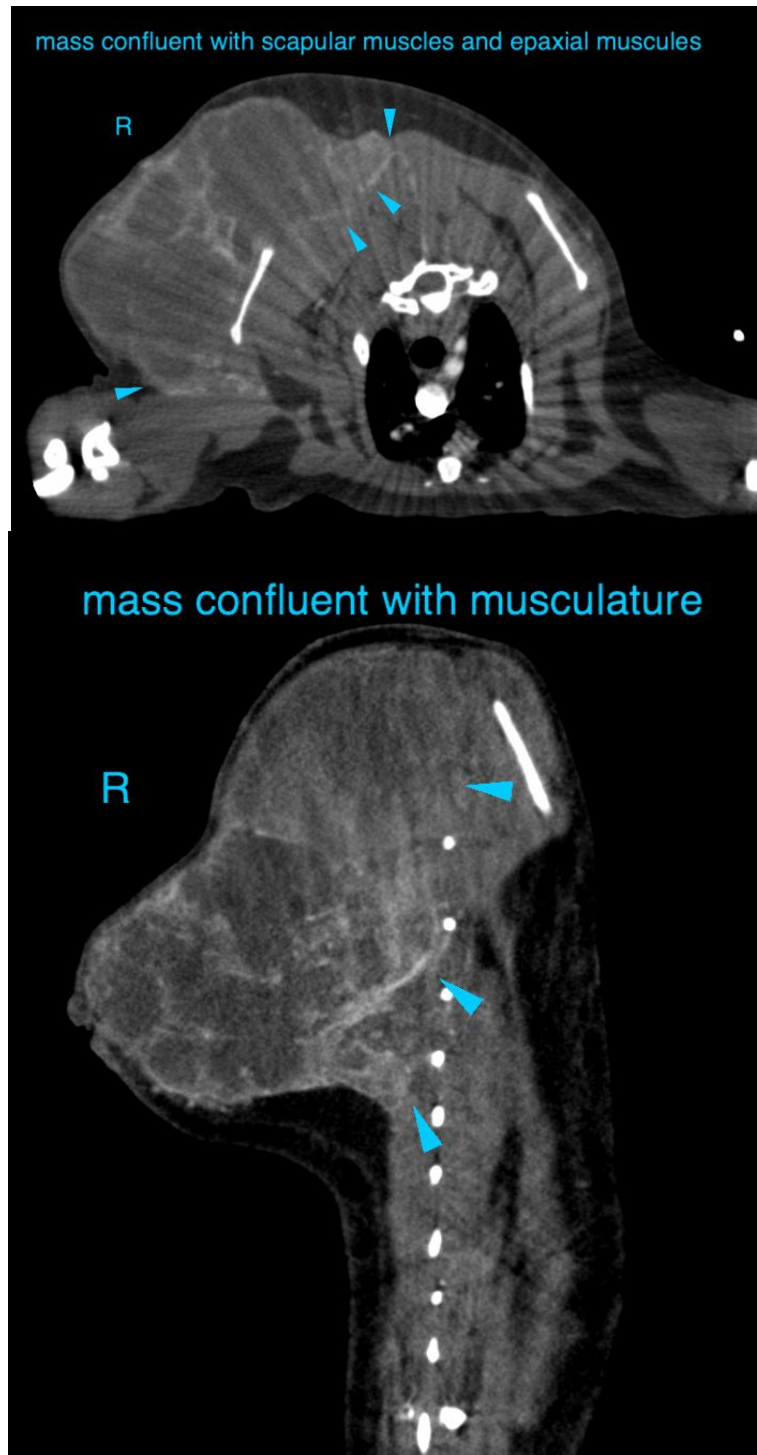
Jennifer Shuck, DVM

INVOICE

55805

DATE

12-23-22





PATIENT

Elly Bingham

The information and recommendations provided are based on the images presented by the referring veterinarian/sonographer. No evaluation can be communicated regarding pathology that was not visible in the image/video clips provided.

SPECIES

Feline

Thank you for this referral. If the clinical or image interpretation does not parallel your findings or if I can be of any further assistance please contact me.

BREED

DSH

Sebastian Schaub, Sebastian Schaub, DVM, Dr. med. vet. DipECVDI
sebast.schaub@gmail.com

SEX

Female Spayed

AGE

4 Years

INTERPRETED BY

Sebastian Schaub, DVM
Dr. med. vet. DipECVDI

HOSPITAL NAME

Parrish Creek
Veterinary Clinic

REFERRING VET

Jennifer Shuck, DVM

INVOICE

55805

DATE

12-23-22