



PATIENT PRESENTING CLINICAL SIGNS

Thumper Polakowski Yesterday patient presented after owner's came home to rabbits eye bulging. IOP- OS 73 mmHG OD 18 mmHg Not eating/drinking in hospital On supportive care
SPECIES Abnormal PE/Chem/CBC/UA Results: CBC/Chem 18/Lytes CA 12.6, GLOB 3.8, ALT 151, ALKP 36, CHOL 24, MCHC 30.3, RETIC 64.3, WBC 17.61, HETERO 9.35, LYM 0.80, MONO 3.28, EOS 3.95, BASO 0.23, PLT 600

Lagomorph **COMPUTED TOMOGRAPHY OF THE SKULL**

A high resolution pre- and post-contrast CT study of the skull is provided for review.

BREED **COMPUTED TOMOGRAPHIC FINDINGS**

Lionhead Triadan 208-211, 307-309 are absent and retained fragments of the roots are seen within the alveolar crest, presenting resorptive lesions and ankylosis. The crown of triadan 206 is significantly elongated and presents a curved conformation, oriented towards the buccal region – there is a pouch like defect of the buccal soft tissues, filled with foamy soft tissue material. Irregular bullous widening of the alveolar bone of the left body of the mandible level with the absent premolar teeth is seen. The periodontal space of triadan 310 is widened. The right premolar and molar teeth present a mild to moderate retrograde growth of the tooth roots.

SEX Male

AGE 9 Years Along the left mandible, a significant soft tissue swelling is seen, post contrast administration there is a heterogeneous contrast enhancement pattern sparing multiple fluid attenuating regions – extending medially and laterally along the ramus of the mandible caudally and dorsally into the ventral aspect of the left orbit. The left ocular bulb is displaced dorsally and laterally by the mass effect. The right parotid salivary duct is moderately distended and contains a small amount of gas.

INTERPRETED BY Sebastian Schaub, DVM Dr. med. vet. DipECVDI
 The nasal cavity presents the expected aerated spaces between thin & even conchae and turbinates with smooth mucosal lining.

HOSPITAL NAME Both temporomandibular joints present congruent joint spaces with even subchondral bone surfaces and are considered within normal limits.

Catskill Veterinary Services, PLLC In the left tympanic bulla, a small amount of gravity dependent soft tissue material is appreciated.. The external ear canals are within normal limits.

REFERRING VET **COMPUTED TOMOGRAPHIC DIAGNOSIS**

- Dr. D'Abbraccio
- Marked elongation and lateral growth triadan 206 with laceration of the left cheek
 - Significant soft tissue swelling with multiple cavitory regions and left sided retrobulbar extend
 - Secondary left sided exophthalmos
 - Absent triadan 208-211, 307-309 with remaining parts of the roots that are ankylotic and present regions of resorption
 - Moderate retrograde dental growth right mandibular premolar and molar teeth
 - Mild left sided otitis media, Grad I Richardson 2019

INVOICE **INTERPRETATION OF THE FINDINGS & FURTHER RECOMMENDATIONS**

55808 The main finding is the marked elongation of the crown of triadan 206, impinging and lacerating the left cheek that might be a trigger for the abscess formation and swelling along the left buccal region with retrobulbar extension – explaining the presenting clinical signs. Preceding dental disease and remodeling of the alveolar bone ± infection may serve as additional trigger for the

DATE

12-22-22



PATIENT

Thumper Polakowski

swelling. Recommend trimming and/or extracting the dental element 206 – depending on the clinical findings. Surgical drainage of the abscess level with the ramus of the mandible should be considered as well.

SPECIES

Lagomorph

BREED

Lionhead

SEX

Male

AGE

9 Years

INTERPRETED BY

Sebastian Schaub, DVM
Dr. med. vet. DipECVDI

HOSPITAL NAME

Catskill Veterinary
Services, PLLC

REFERRING VET

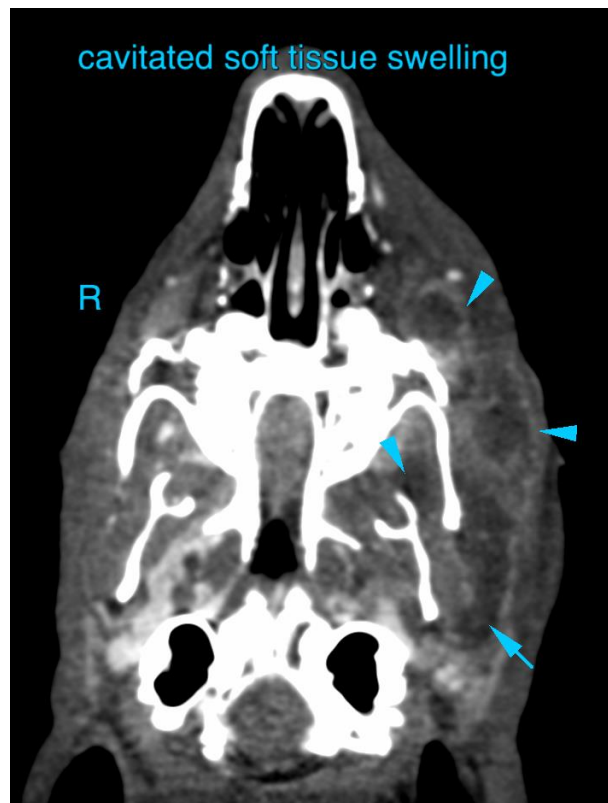
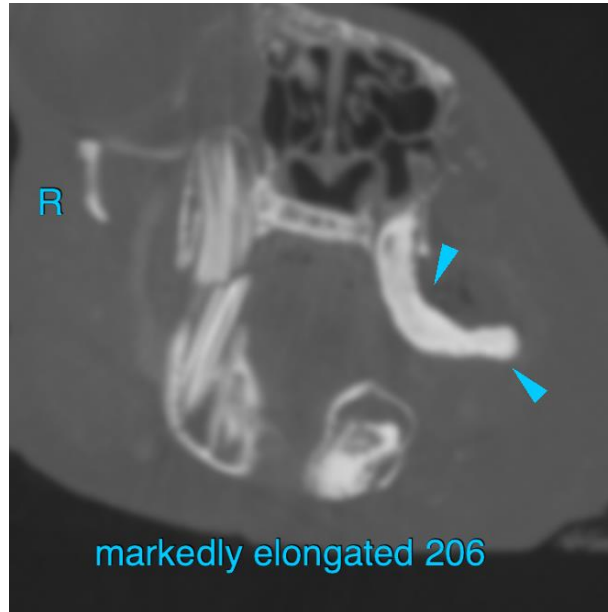
Dr. D'Abbraccio

INVOICE

55808

DATE

12-22-22





PATIENT

Thumper Polakowski

SPECIES

Lagomorph

BREED

Lionhead

SEX

Male

AGE

9 Years

INTERPRETED BY

Sebastian Schaub, DVM
Dr. med. vet. DipECVDI

HOSPITAL NAME

Catskill Veterinary
Services, PLLC

REFERRING VET

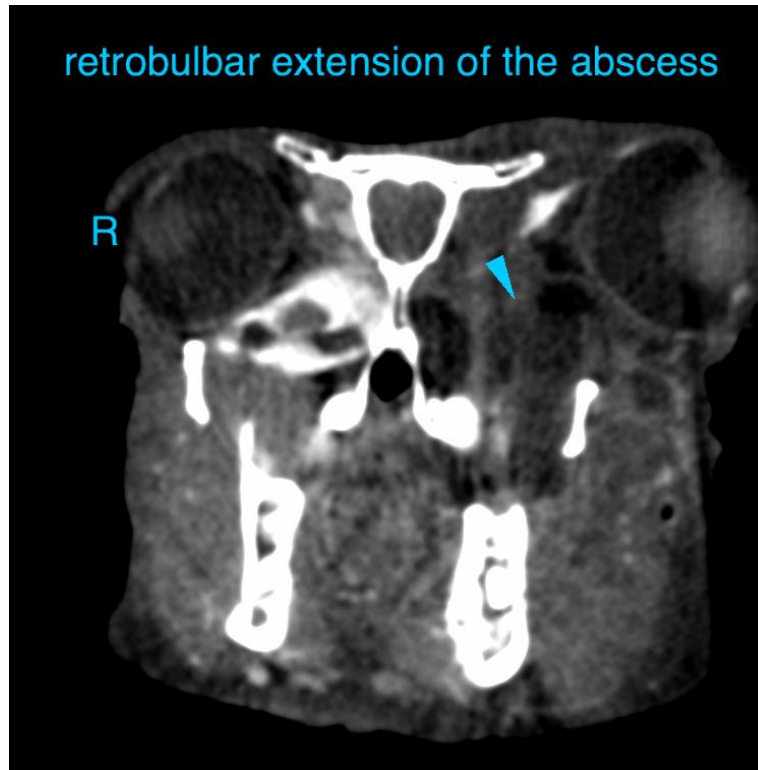
Dr. D'Abbraccio

INVOICE

55808

DATE

12-22-22



The information and recommendations provided are based on the images presented by the referring veterinarian/sonographer. No evaluation can be communicated regarding pathology that was not visible in the image/video clips provided.

Thank you for this referral. If the clinical or image interpretation does not parallel your findings or if I can be of any further assistance please contact me.

Sebastian Schaub, Sebastian Schaub, DVM, Dr. med. vet. DipECVDI
sebast.schaub@gmail.com