



PATIENT PRESENTING CLINICAL SIGNS

Scout Myers Firm swelling above upper right pm4

COMPUTED TOMOGRAPHY OF THE SKULL

SPECIES A high resolution pre- and post-contrast CT study of the skull is provided for review.

Canine **COMPUTED TOMOGRAPHIC FINDINGS**

The tooth elements 105, 106, 205, 206 are absent. Triadan 107&207 present a widened periodontal space of the mesial root.

BREED

Cavalier King Charles Spaniel

The alveolar process of the right maxillary bone, level with triadan 108 and 109, an expansile, geographic osteolytic lesion is appreciated, perforating the cortex laterally. Post contrast administration, the expansile bone lesion presents a thin contrast enhancing capsule and hypoattenuating center.

SEX

The nasal cavity presents the expected aerated spaces between thin & even conchae and turbinates with smooth mucosal lining.

Spayed Female

Both temporomandibular joints present congruent joint spaces with even subchondral bone surfaces and are considered within normal limits.

AGE

6 Years

Both tympanic bullae contains soft tissue attenuating material, L>>R. The external ear canals are within normal limits.

The brain presents no deviation from normal anatomy and symmetry. The brain parenchyma is homogeneous and within normal limits for attenuation and distribution of contrast enhancement. The ventricular system is non-dilated and symmetric.

INTERPRETED BY

Sebastian Schaub, DVM
Dr. med. vet. DipECVDI

The submandibular and medial retropharyngeal lymph nodes are small and elongated with a normal short-to-long-axis-ratio is < 0.5, the attenuation and contrast enhancement pattern is uniform.

COMPUTED TOMOGRAPHIC DIAGNOSIS

HOSPITAL NAME

Mobile Pet Imaging

- Monostotic semiaggressive expansile osteolytic lesion alveolar process right maxillary bone with fluid attenuating center; no evidence of perforation of the nasal cavity
- Bilateral periodontal disease 107&207
- Otitis media, L>>R – likely primary secretory
- Multiple absent teeth, see above

REFERRING VET

Meaux

INTERPRETATION OF THE FINDINGS & FURTHER RECOMMENDATIONS

INVOICE

55783

The expansile bone lesion of the alveolar process of the right maxillary bone appears to be cavitated and can present benign osseous cyst like lesion or lateral periodontal cyst – will warrant extraction of the associated teeth and curettage of the suspected cyst. However, to rule out malignant transformation such as squamous cell carcinoma, biopsy is mandatory.

DATE

12-22-22



PATIENT

Scout Myers

SPECIES

Canine

BREED

Cavalier King Charles
Spaniel

SEX

Spayed Female

AGE

6 Years

INTERPRETED BY

Sebastian Schaub, DVM
Dr. med. vet. DipECVDI

HOSPITAL NAME

Mobile Pet Imaging

REFERRING VET

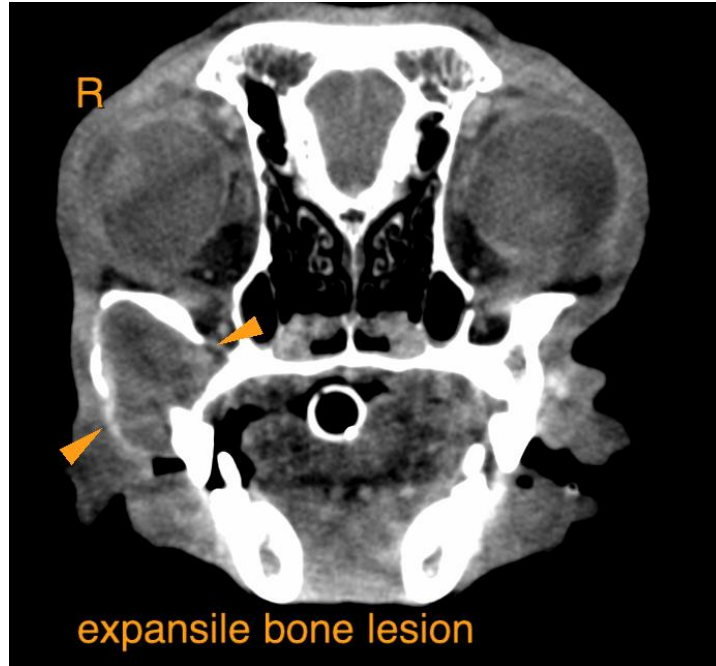
Meaux

INVOICE

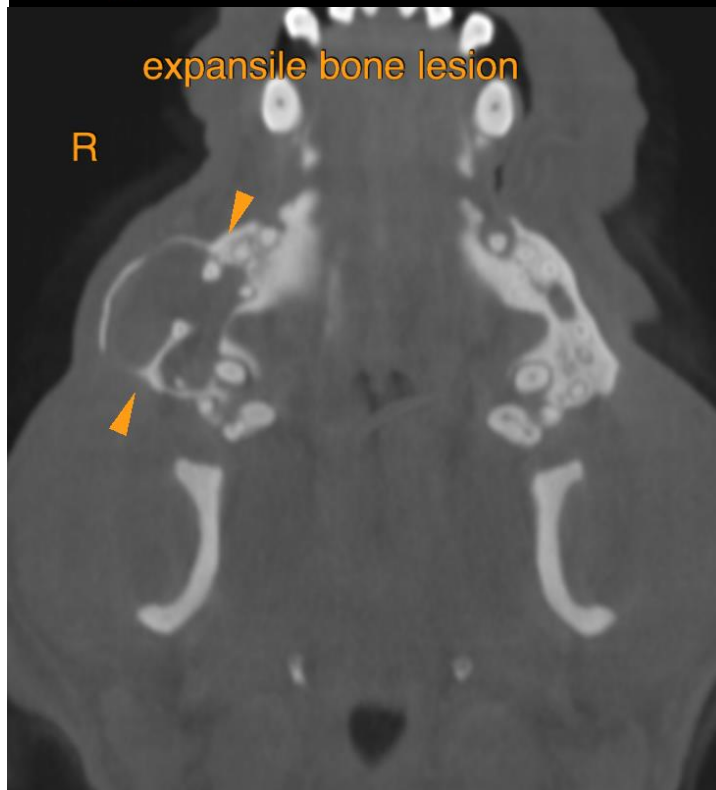
55783

DATE

12-22-22



expansile bone lesion



expansile bone lesion



PATIENT

Scout Myers

The information and recommendations provided are based on the images presented by the referring veterinarian/sonographer. No evaluation can be communicated regarding pathology that was not visible in the image/video clips provided.

SPECIES

Canine

Thank you for this referral. If the clinical or image interpretation does not parallel your findings or if I can be of any further assistance please contact me.

BREED

Cavalier King Charles
Spaniel

Sebastian Schaub, Sebastian Schaub, DVM, Dr. med. vet. DipECVDI
sebast.schaub@gmail.com

SEX

Spayed Female

AGE

6 Years

INTERPRETED BY

Sebastian Schaub, DVM
Dr. med. vet. DipECVDI

HOSPITAL NAME

Mobile Pet Imaging

REFERRING VET

Meaux

INVOICE

55783

DATE

12-22-22