



PATIENT

Ruby Richard

PRESENTING CLINICAL SIGNS

Grade 3-4 heart murmur, has had seizure like episode twice, one in September and the second one a week ago. Need to rule out DCM.

SPECIES

Canine

RADIOGRAPHIC STUDY OF THE THORAX

Radiographs of the thorax in three imaging planes are provided for review.

BREED

Shih Tzu

RADIOGRAPHIC FINDINGS

The surrounding bony structures are within normal limits.

The extrathoracic soft tissues present homogeneous without abnormalities.

The caudal contour of the cardiac silhouette is steep and the caudal cardiac waist is lost. The left atrium is mildly prominent. The vertebral heart score is 10.8. The pulmonary vasculature is within normal limits.

SEX

Spayed Female

The cranial mediastinum presents the expected soft tissue opacity. The mediastinal width is less than twice the width of the vertebral column at the same level.

AGE

12 Years

The trachea is normal in diameter and presents the anticipated course. The luminal outline of the trachea is smooth.

The bronchial tree presents with thin walls and tapers uniformly towards the periphery as expected.

INTERPRETED BY

Sebastian Schaub, DVM
Dr. med. vet. DipECVDI

The lung parenchyma presents the expected architecture and opacity; the intrapulmonary vascular branching is seen up to the third order lung vessels.

The diaphragm is well delineated with even surface and the expected mild cranial bulging of the diaphragmatic cupola.

HOSPITAL NAME

Truscott Animal
Hospital

RADIOGRAPHIC DIAGNOSIS

- Mild left sided cardiomegaly without signs of decompensation

REFERRING VET

Dr. Medhat Meawad

INTERPRETATION OF THE FINDINGS & FURTHER RECOMMENDATIONS

The radiographic study presents signs of mild left cardiac enlargement, the most common cause is mitral valve insufficiency due to myxomatous mitral valve degeneration. A cardiac echo might be used for further assessment of cardiac chamber size and function.

INVOICE

55811

DATE

12-22-22



PATIENT

Ruby Richard

SPECIES

Canine

BREED

Shih Tzu

SEX

Spayed Female

AGE

12 Years

INTERPRETED BY

Sebastian Schaub, DVM
Dr. med. vet. DipECVDI

HOSPITAL NAME

Truscott Animal
Hospital

REFERRING VET

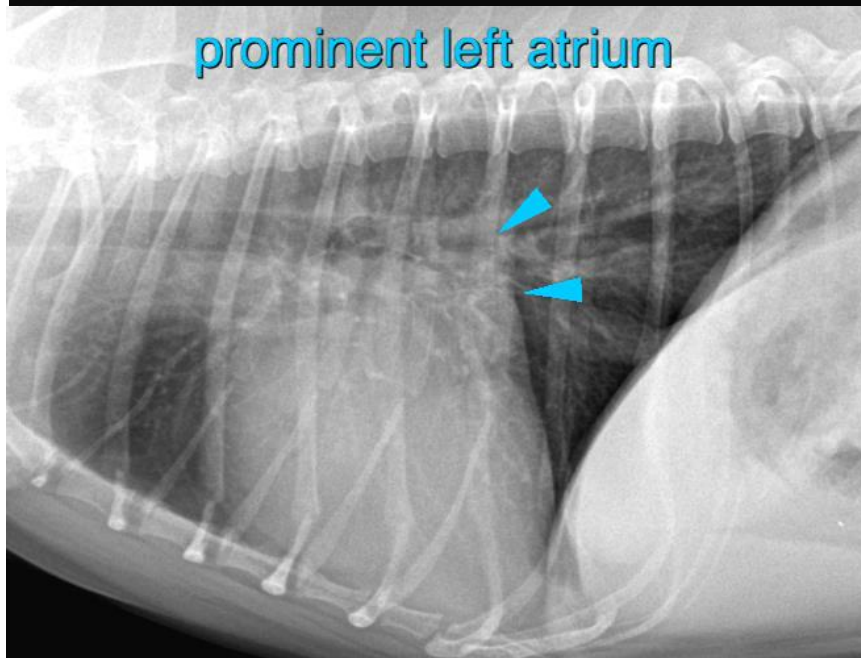
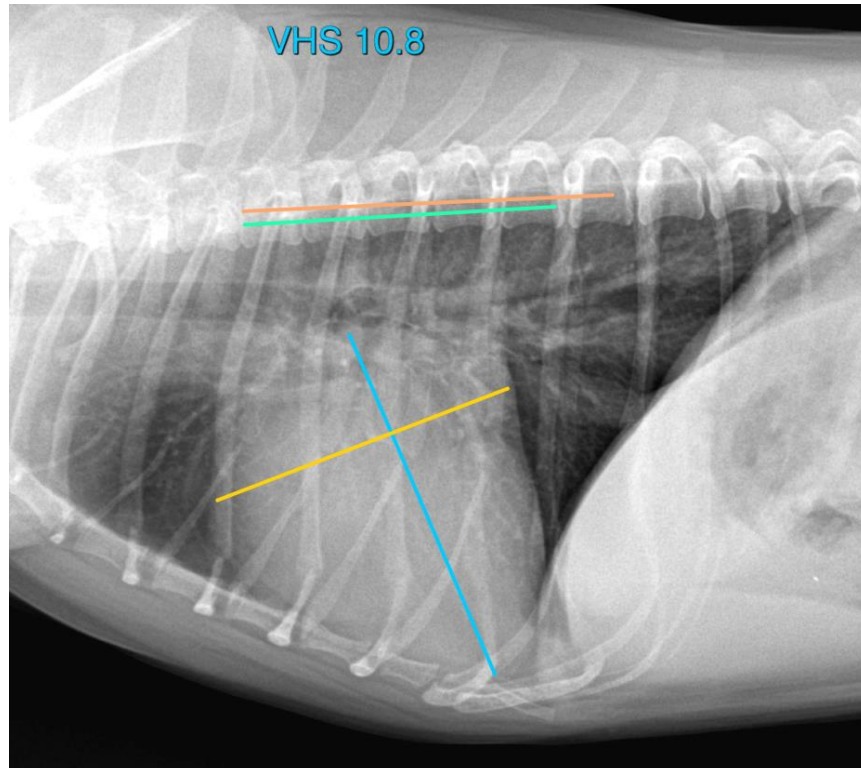
Dr. Medhat Meawad

INVOICE

55811

DATE

12-22-22





PATIENT

Ruby Richard

The information and recommendations provided are based on the images presented by the referring veterinarian/sonographer. No evaluation can be communicated regarding pathology that was not visible in the image/video clips provided.

SPECIES

Canine

Thank you for this referral. If the clinical or image interpretation does not parallel your findings or if I can be of any further assistance please contact me.

Sebastian Schaub, Sebastian Schaub, DVM, Dr. med. vet. DipECVDI
sebast.schaub@gmail.com

BREED

Shih Tzu

SEX

Spayed Female

AGE

12 Years

INTERPRETED BY

Sebastian Schaub, DVM
Dr. med. vet. DipECVDI

HOSPITAL NAME

Truscott Animal
Hospital

REFERRING VET

Dr. Medhat Meawad

INVOICE

55811

DATE

12-22-22