

**PATIENT**Emma Dominguez  
Rodriguez**PRESENTING CLINICAL SIGNS**Four days ago owner stepped on second digit left front limb. Toe is swollen and pet is painful.  
20r6**SPECIES**

Canine

**RADIOGRAPHIC STUDY OF THE FRONT PAWS**

Radiographs of the front paws in two orthogonal imaging planes are provided for review.

**BREED**German Shorthaired  
Pointer**RADIOGRAPHIC FINDINGS**

The second digit of the left front paw presents with a moderate circumferential, homogeneous soft tissue swelling. In the mediolateral view, a radiolucent line is seen running through the base of the unguis process of the distal phalanx of the second digit – not appreciated in the dorsopalmar view. The osseous structures of the second digit of the left front paw present without abnormalities.

The remainder of the osseous and soft tissue structures of both front limbs present without abnormalities.

**SEX**

Spayed Female

**RADIOGRAPHIC DIAGNOSIS**

- Soft tissue swelling second digit left front paw
- Possible transverse fracture base of unguis process distal phalanx second digit left front paw versus Mach effect

**AGE**

1 Year

**INTERPRETATION OF THE FINDINGS & FURTHER RECOMMENDATIONS**

There is a soft tissue swelling in combination with the history traumatic origin is likely, and there is a possible fracture of the unguis process, but the diagnosis of fracture is not definitive as it may present a Mach effect caused by superimposition with the margins of the pads of the third and fourth phalanx. Repeating the mediolateral projection of the second digit of the left front paw without superimposition by the other digits can be used to rule in/out fracture entirely. Rule out laceration of nailbed, triggering onychitis as source for the swelling as well.

**INTERPRETED BY**Sebastian Schaub, DVM  
Dr. med. vet. DipECVDI**HOSPITAL NAME**Alejandrino Animal  
Hospital**REFERRING VET**

Dra Garcia

**INVOICE**

55779

**DATE**

12-22-22



**PATIENT**

Emma Dominguez  
Rodriguez

**SPECIES**

Canine

**BREED**

German Shorthaired  
Pointer

**SEX**

Spayed Female

**AGE**

1 Year

**INTERPRETED BY**

Sebastian Schaub, DVM  
Dr. med. vet. DipECVDI

**HOSPITAL NAME**

Alejandrino Animal  
Hospital

**REFERRING VET**

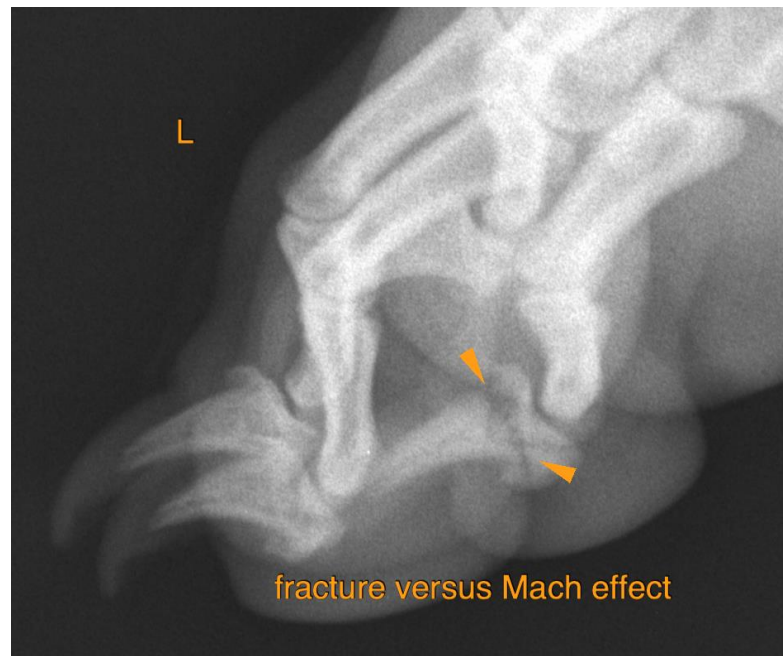
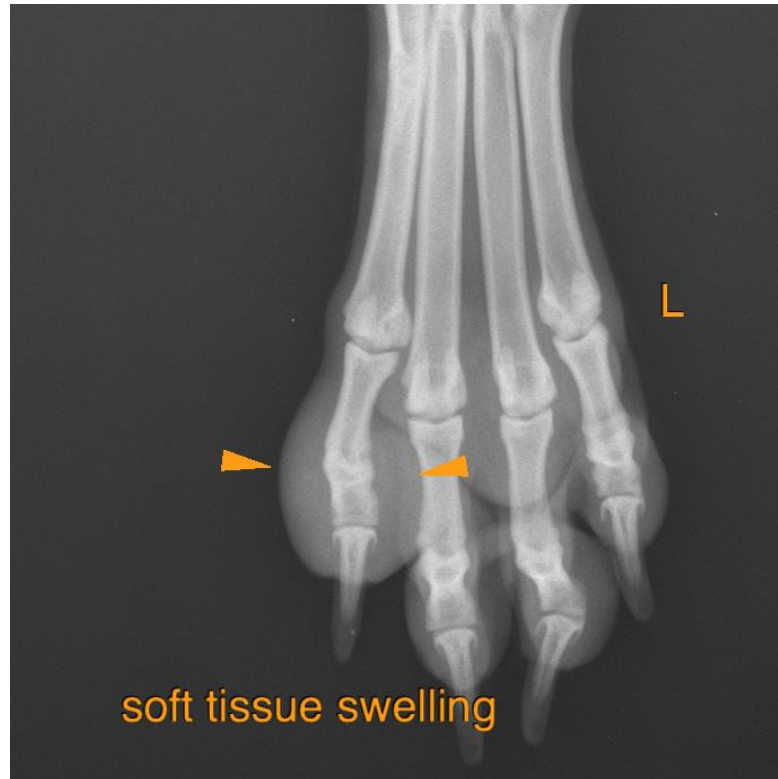
Dra Garcia

**INVOICE**

55779

**DATE**

12-22-22





**PATIENT**

Emma Dominguez  
Rodriguez

**SPECIES**

Canine

**BREED**

German Shorthaired  
Pointer

**SEX**

Spayed Female

**AGE**

1 Year

**INTERPRETED BY**

Sebastian Schaub, DVM  
Dr. med. vet. DipECVDI

**HOSPITAL NAME**

Alejandrino Animal  
Hospital

**REFERRING VET**

Dra Garcia

**INVOICE**

55779

**DATE**

12-22-22

The information and recommendations provided are based on the images presented by the referring veterinarian/sonographer. No evaluation can be communicated regarding pathology that was not visible in the image/video clips provided.

Thank you for this referral. If the clinical or image interpretation does not parallel your findings or if I can be of any further assistance please contact me.

**Sebastian Schaub**, Sebastian Schaub, DVM, Dr. med. vet. DipECVDI  
sebast.schaub@gmail.com