

**PATIENT**

Beau Passfield

PRESENTING CLINICAL SIGNS

We are resending x-rays for this patient because the specialist wanted us to send better views for the shoulder. On going limping in the left front leg. Again this is a repeat of the x-rays we have previously sent but with better views.

SPECIES

Canine

RADIOGRAPHIC STUDY OF THE SHOULDER JOINTS

Radiographs of the left shoulder joint in two imaging planes are provided for review.

BREED

Boxer

RADIOGRAPHIC FINDINGS

The proximal metaphysis of the left humerus presents an ill-defined zone with osteolysis – most accentuated in the medial aspect – with lysis of the cortex at the same level. Immature periosteal new bone formation is seen along the proximal metaphysis and diaphysis of the left humerus.

SEX

Neutered Male

A well-defined mineral opaque body is seen at the cranial aspect of the greater tubercle of the left humerus.

RADIOGRAPHIC DIAGNOSIS

- Monostotic aggressive osteolytic lesion proximal left humerus

AGE

11 Years

INTERPRETATION OF THE FINDINGS & FURTHER RECOMMENDATIONS

The repeated radiographic study of the left shoulder joint is confirming the diagnosis of an aggressive bone lesion and primary osseous neoplasia is the diagnosis – such as osteosarcoma, chondrosarcoma, fibrosarcoma. FNA sampling ± bone biopsy can be performed to confirm the diagnosis. Consider full tumor staging.

INTERPRETED BY

Sebastian Schaub, DVM
Dr. med. vet. DipECVDI

HOSPITAL NAME

Wilson Road
Veterinary Clinic

REFERRING VET

Dr. Yessa

INVOICE

55802

DATE

12-22-22



PATIENT

Beau Passfield

SPECIES

Canine

BREED

Boxer

SEX

Neutered Male

AGE

11 Years

INTERPRETED BY

Sebastian Schaub, DVM
Dr. med. vet. DipECVDI

HOSPITAL NAME

Wilson Road
Veterinary Clinic

REFERRING VET

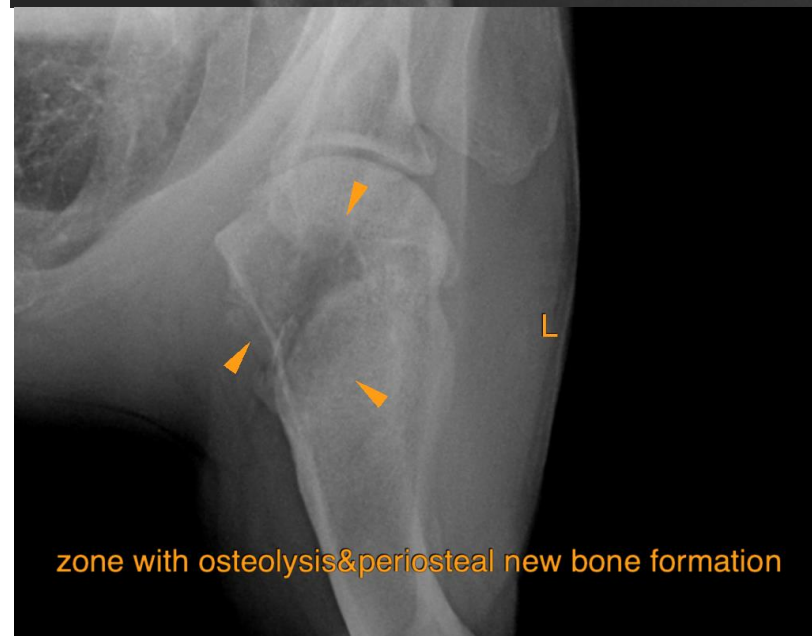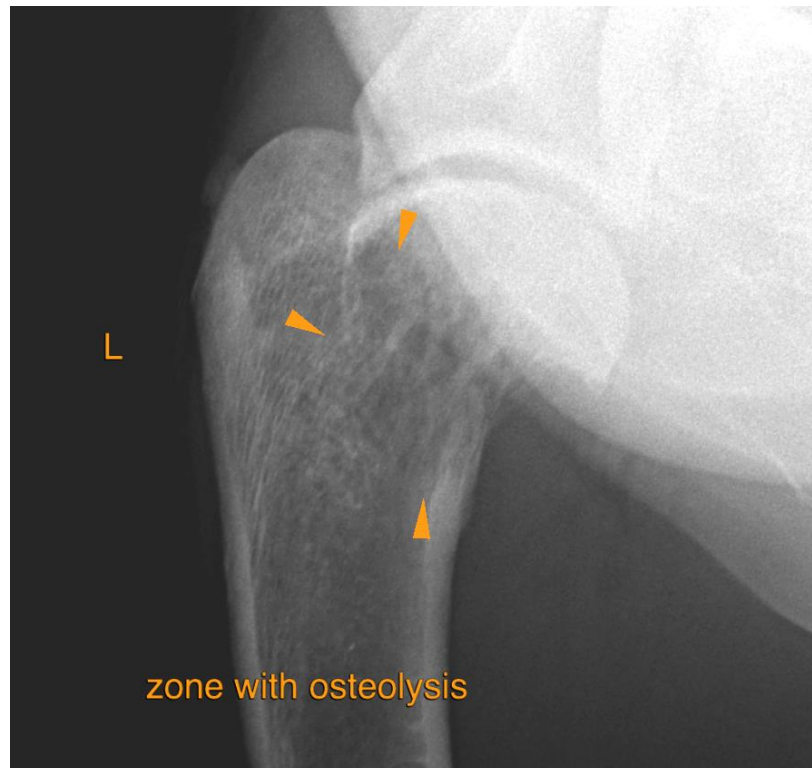
Dr. Yessa

INVOICE

55802

DATE

12-22-22





PATIENT

Beau Passfield

The information and recommendations provided are based on the images presented by the referring veterinarian/sonographer. No evaluation can be communicated regarding pathology that was not visible in the image/video clips provided.

Thank you for this referral. If the clinical or image interpretation does not parallel your findings or if I can be of any further assistance please contact me.

SPECIES

Canine

Sebastian Schaub, Sebastian Schaub, DVM, Dr. med. vet. DipECVDI
sebast.schaub@gmail.com

BREED

Boxer

SEX

Neutered Male

AGE

11 Years

INTERPRETED BY

Sebastian Schaub, DVM
Dr. med. vet. DipECVDI

HOSPITAL NAME

Wilson Road
Veterinary Clinic

REFERRING VET

Dr. Yessa

INVOICE

55802

DATE

12-22-22