



**PATIENT**

Louie Panek

**PRESENTING CLINICAL SIGNS**

Sudden onset of neurologic and wobbly in back end  
Abnormal PE/Chem/CBC/UA Results: Blood pending

**SPECIES**

Feline

**RADIOGRAPHIC STUDY OF THE LUMBAR SPINE**

A lateral projection of the lumbar spine is provided for review.

**BREED**

DSH

**RADIOGRAPHIC FINDINGS**

The vertebral endplates of the lumbosacral junction present moderate spondylosis formation and multifocal mild spondylosis formation is seen along the lumbar spine.

The intervertebral disc space L1/L2 is mildly narrowed.

**SEX**

MN

**RADIOGRAPHIC DIAGNOSIS**

- Possible discopathy L1/L2
- Spondylosis deformans

**AGE**

10 Years

**INTERPRETATION OF THE FINDINGS & FURTHER RECOMMENDATIONS**

The possible discopathy L1/L2 can be associated with or without compressive myelopathy as potential source for the neurological deficits. Underlying cardiac disease with thromboembolic insult might be a potential as well.. Cross-sectional imaging might be used if clinical signs deteriorate and to rule out malignancy not appreciated by radiography.

**INTERPRETED BY**

Sebastian Schaub, DVM  
Dr. med. vet. DipECVDI

**HOSPITAL NAME**

Hamburg Veterinary  
Clinic

**REFERRING VET**

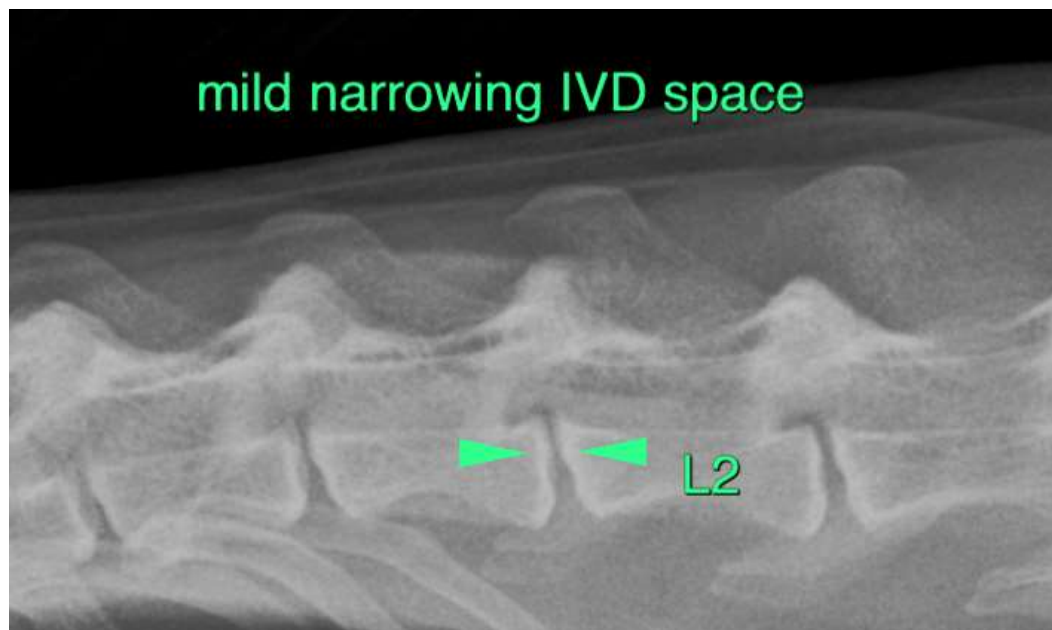
Dr. Branning

**INVOICE**

49206

**DATE**

12-22-21





**PATIENT**

Louie Panek

**SPECIES**

Feline

**BREED**

DSH

**SEX**

MN

**AGE**

10 Years

**INTERPRETED BY**

Sebastian Schaub, DVM  
Dr. med. vet. DipECVDI

**HOSPITAL NAME**

Hamburg Veterinary  
Clinic

**REFERRING VET**

Dr. Branning

**INVOICE**

49206

**DATE**

12-22-21

The information and recommendations provided are based on the images presented by the referring veterinarian. No evaluation can be communicated regarding pathology that was not visible in the image/video clips provided.

Thank you for this referral. If the clinical or image interpretation does not parallel your findings or if I can be of any further assistance please contact me.

**Sebastian Schaub**, Sebastian Schaub, DVM, Dr. med. vet. DipECVDI  
sebast.schaub@gmail.com