



PATIENT

Larry Larkin

SPECIES

Canine

BREED

Labrador Retriever

SEX

MN

AGE

11 Years

INTERPRETED BY

Sebastian Schaub, DVM
Dr. med. vet. DipECVDI

HOSPITAL NAME

Healing Paws

REFERRING VET

Jennifer Levitsky

INVOICE

49196

DATE

12-22-21

PRESENTING CLINICAL SIGNS

One year history of liver mass. Having flare up of allergic skin disease currently. Begin tx for met resistant coag neg staph skin infection with baytril and doxycycline for last 2 weeks. Skin is improving. Started to have low grade cough about 10-14 days ago. Somewhat intermittent and staying about the same level. Eating well. Energy level ok. Goes for walk and that doesn't seem to elicit cough.

RADIOGRAPHIC STUDY OF THE THORAX

Radiographs of the thorax in two orthogonal imaging planes are provided for review.

RADIOGRAPHIC FINDINGS

The surrounding bony structures are within normal limits.

The extrathoracic soft tissues present homogeneous without abnormalities.

The heart is of normal size and shape, there is no evidence of cardiac chamber or vascular enlargement. The pulmonary vasculature is within normal limits.

The cranial mediastinum presents the expected soft tissue opacity. The mediastinal width is less than twice the width of the vertebral column at the same level.

The trachea is normal in diameter and presents the anticipated course. The luminal outline of the trachea is smooth.

The bronchial tree presents with thin walls and tapers uniformly towards the periphery as expected.

The lung parenchyma presents the expected architecture and opacity; the intrapulmonary vascular branching is seen up to the third order lung vessels.

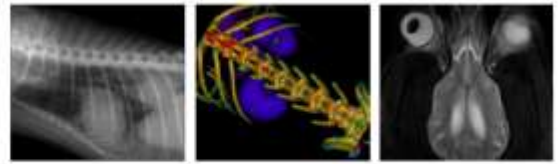
The diaphragm is well delineated with even surface and the expected mild cranial bulging of the diaphragmatic cupola.

RADIOGRAPHIC DIAGNOSIS

- Normal thorax

INTERPRETATION OF THE FINDINGS & FURTHER RECOMMENDATIONS

The radiographic study of the thorax is negative for pathology. However, negative radiographs do not rule out potential tracheitis or bronchitis completely.



PATIENT

Larry Larkin

SPECIES

Canine

The information and recommendations provided are based on the images presented by the referring veterinarian. No evaluation can be communicated regarding pathology that was not visible in the image/video clips provided.

BREED

Labrador Retriever

Thank you for this referral. If the clinical or image interpretation does not parallel your findings or if I can be of any further assistance please contact me.

Sebastian Schaub, Sebastian Schaub, DVM, Dr. med. vet. DipECVDI
sebast.schaub@gmail.com

SEX

MN

AGE

11 Years

INTERPRETED BY

Sebastian Schaub, DVM
Dr. med. vet. DipECVDI

HOSPITAL NAME

Healing Paws

REFERRING VET

Jennifer Levitsky

INVOICE

49196

DATE

12-22-21