



PATIENT

Indy Riccardi

PRESENTING CLINICAL SIGNS

Oral mass noted 6-8 months ago. Worsening in the past 3-4 months. Biopsy sent same day. Guidance for surgical correction needed. Pre and post skull images
Abnormal PE/Chem/CBC/UA Results: wnl

SPECIES

Canine

COMPUTED TOMOGRAPHY OF THE SKULL

A high resolution pre- and post-contrast CT study of the skull is provided for review.

BREED

American Pit Bull

COMPUTED TOMOGRAPHIC FINDINGS

Triadan 104, 308 and 408 are absent. A supernumerary tooth element triadan 201 is seen. Abrasion of the crown of mandibular canine teeth is seen. The pulp cavity of triadan 404 is mildly widened in comparison to triadan 304 and there is a moderate periapical widening of the periodontal space of triadan 404.

SEX

MN

The nasal cavity presents the expected aerated spaces between thin & even conchae and turbinates with smooth mucosal lining.

AGE

7

Both temporomandibular joints present congruent joint spaces with even subchondral bone surfaces and are considered within normal limits.

INTERPRETED BY

Sebastian Schaub, DVM
Dr. med. vet. DipECVDI

Both tympanic bullae are aerated, the mucosal lining is not seen, the bony wall is smooth and thin. The external ear canals are within normal limits.

The brain presents no deviation from normal anatomy and symmetry. The brain parenchyma is homogeneous and within normal limits for attenuation and distribution of contrast enhancement. The ventricular system is non-dilated and symmetric.

HOSPITAL NAME

Stone Cottage
Veterinary Hospital

The submandibular and medial retropharyngeal lymph nodes are small and elongated with a normal short-to-long-axis-ratio is < 0.5, the attenuation and contrast enhancement pattern is uniform.

COMPUTED TOMOGRAPHIC DIAGNOSIS

REFERRING VET

Spaccarelli

- Periapical abscess triadan 404
- Supernumerary triadan 201
- Absent triadan 104, 308 and 408

INTERPRETATION OF THE FINDINGS & FURTHER RECOMMENDATIONS

INVOICE

49207

An oral mass cannot be appreciated in the current CT study of the skull, it might be effaced by the close contact with the lips or tongue. No osteolytic lesions are appreciated but periapical lysis level with triadan 404 most consistent with periapical abscess formation.

DATE

12-22-21



PATIENT

Indy Riccardi

SPECIES

Canine

BREED

American Pit Bull

SEX

MN

AGE

7

INTERPRETED BY

Sebastian Schaub, DVM
Dr. med. vet. DipECVDI

HOSPITAL NAME

Stone Cottage
Veterinary Hospital

REFERRING VET

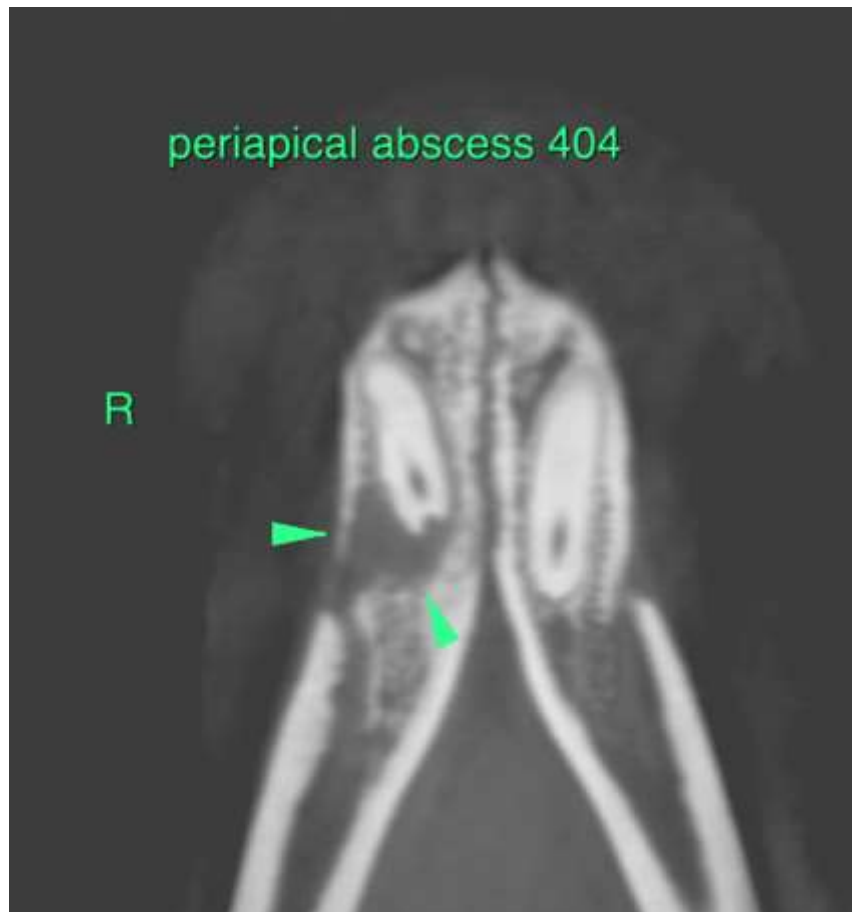
Spaccarelli

INVOICE

49207

DATE

12-22-21



The information and recommendations provided are based on the images presented by the referring veterinarian. No evaluation can be communicated regarding pathology that was not visible in the image/video clips provided.

Thank you for this referral. If the clinical or image interpretation does not parallel your findings or if I can be of any further assistance please contact me.

Sebastian Schaub, Sebastian Schaub, DVM, Dr. med. vet. DipECVDI
sebast.schaub@gmail.com