



PATIENT

Willow Skarban

PRESENTING CLINICAL SIGNS

Limping on right hind leg for 1 week, rule out ACL Vs. patellar luxation. Palpating right hind leg, could be positive for partial tear

SPECIES

Canine

RADIOGRAPHIC STUDY OF THE STIFLE JOINTS

Radiographs of the thorax in right stifle joint in two orthogonal imaging planes and the left stifle joint in a craniocaudal view are provided for review.

BREED

Toy Poodle

RADIOGRAPHIC FINDINGS

The periarticular bones of both stifle joints present moderate osteophyte new bone formation. The patella of both stifle joints is superimposed on the soft tissues medial to the medial femoral condyle. At the lateral aspect of the left femoral condyles, multiple small (<3 mm) mineral opaque bodies are seen in the imaging plane of the joint capsule. Significant cranial subluxation of the right tibia is appreciated. The right stifle joint presents a moderate intracapsular soft tissue swelling, effacing the infrapatellar fat pad.

SEX

Female

RADIOGRAPHIC DIAGNOSIS

- Cranial subluxation right tibia
- Medial patellar luxation stifle joints bilaterally
- Moderate articular swelling right stifle joint
- Moderate degenerative osteoarthritis stifle joints bilaterally
- Suspect small metaplasia joint capsule left stifle joint

AGE

7 Years

INTERPRETED BY

Sebastian Schaub, DVM
Dr. med. vet. DipECVDI

INTERPRETATION OF THE FINDINGS & FURTHER RECOMMENDATIONS

The main finding is the cranial subluxation of the right tibia, indicating failure of the cranial cruciate ligament – a plausible explanation for the acute clinical signs.

HOSPITAL NAME

Truscott Animal Hospital

The clinical relevance of the bilateral medial patellar luxation is unclear and likely not related with the recent clinical signs.

REFERRING VET

Dr. Medhat Meawad

INVOICE

55773

DATE

12-21-22



PATIENT

Willow Skarban

SPECIES

Canine

BREED

Toy Poodle

SEX

Female

AGE

7 Years

INTERPRETED BY

Sebastian Schaub, DVM
Dr. med. vet. DipECVDI

HOSPITAL NAME

Truscott Animal
Hospital

REFERRING VET

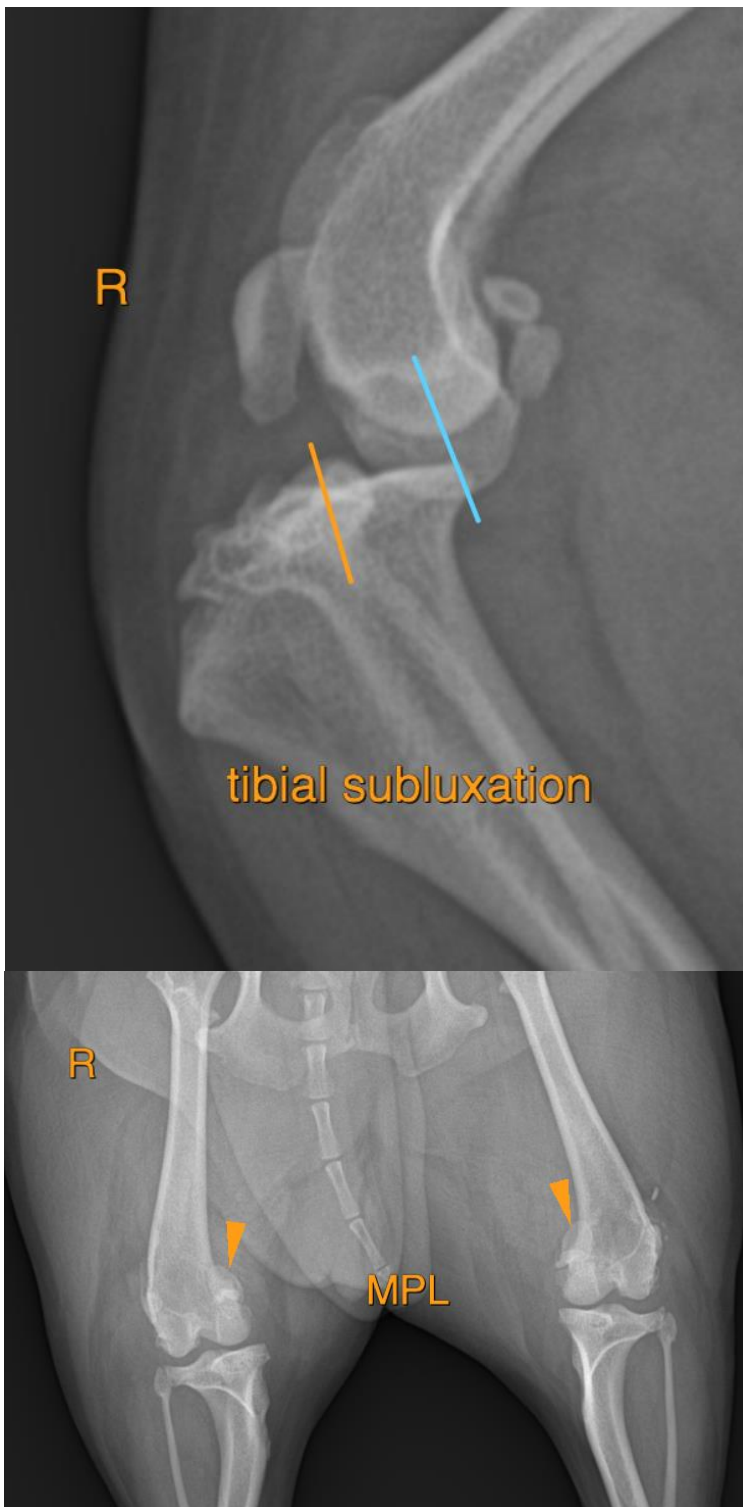
Dr. Medhat Meawad

INVOICE

55773

DATE

12-21-22





PATIENT

Willow Skarban

SPECIES

Canine

The information and recommendations provided are based on the images presented by the referring veterinarian/sonographer. No evaluation can be communicated regarding pathology that was not visible in the image/video clips provided.

BREED

Toy Poodle

Thank you for this referral. If the clinical or image interpretation does not parallel your findings or if I can be of any further assistance please contact me.

Sebastian Schaub, Sebastian Schaub, DVM, Dr. med. vet. DipECVDI
sebast.schaub@gmail.com

SEX

Female

AGE

7 Years

INTERPRETED BY

Sebastian Schaub, DVM
Dr. med. vet. DipECVDI

HOSPITAL NAME

Truscott Animal
Hospital

REFERRING VET

Dr. Medhat Meawad

INVOICE

55773

DATE

12-21-22