



PATIENT

Skye Castellanos

PRESENTING CLINICAL SIGNS

P was presented for decreased appetite and lethargy lasting 3 days. Developed swelling/edema around the neck and face. Fever for 2 days prior to hospitalization. Hx: e. cuniculi infection, treated with Fenbendazole.

SPECIES

Lagomorph

Abnormal PE/Chem/CBC/UA Results: CBC/Chem18/Lytes- Glob 3.1, ALT 78, ALKP 36, TBIL <0.1, Chol 55, RBC 4.37, HGB 9.7, MCV 71.2, MCH 22.2, MCHC 31.2, WBC 0.99, HETERO 0.3, LYM 0.43, MONO 0.15, BASO 0.04

COMPUTED TOMOGRAPHY OF THE SKULL

BREED

Hotot

A high resolution pre- and post-contrast CT study of the skull is provided for review.

COMPUTED TOMOGRAPHIC FINDINGS

The pictured parts of the dentition are complete and unremarkable in all jaw quadrants.

SEX

Female Spayed

A diffuse subcutaneous swelling is seen along the nose/upper lips and ventral aspect of the skull.

In the right nasal cavity, moderate atrophy of the conchal structures is appreciated.

AGE

7

In the post contrast study, multiple small gas inclusions are seen in the rostroventral aspect of the left orbit/region of the left temporomandibular joint – likely iatrogenic with gas trapped in the venous plexus as it is not appreciated in the plain CT study.

Both temporomandibular joints present congruent joint spaces with even subchondral bone surfaces and are considered within normal limits.

INTERPRETED BY

Sebastian Schaub, DVM
Dr. med. vet. DipECVDI

Both tympanic bullae are aerated, the mucosal lining is not seen, the bony wall is smooth and thin. The external ear canals are within normal limits.

A small amount of fluid attenuating material is seen in the trachea.

HOSPITAL NAME

Catskill Veterinary Services, PLLC

COMPUTED TOMOGRAPHIC DIAGNOSIS

- Edematous swelling along the rostral aspect of the viscerocranium and ventral aspect of the skull
- Signs of preceding destructive rhinitis – at this point there is no sign for active rhinitis

REFERRING VET

Dr. Joseph D'Abbraccio

INTERPRETATION OF THE FINDINGS & FURTHER RECOMMENDATIONS

An underlying cause for the swelling along the nose cannot be specified, rule out allergic reaction, bite wound, infectious (e.g. Myxomatosis), neoplastic (e.g. lymphoma) or thrombotic event (e.g. if there was preceding blood sampling from jugular vein). The history of fever might increase the odds for underlying infectious cause.

INVOICE

55769

No abnormalities of the dentition are appreciated.

DATE

12-21-22



PATIENT

Skye Castellanos

SPECIES

Lagomorph

BREED

Hotot

SEX

Female Spayed

AGE

7

INTERPRETED BY

Sebastian Schaub, DVM
Dr. med. vet. DipECVDI

HOSPITAL NAME

Catskill Veterinary
Services, PLLC

REFERRING VET

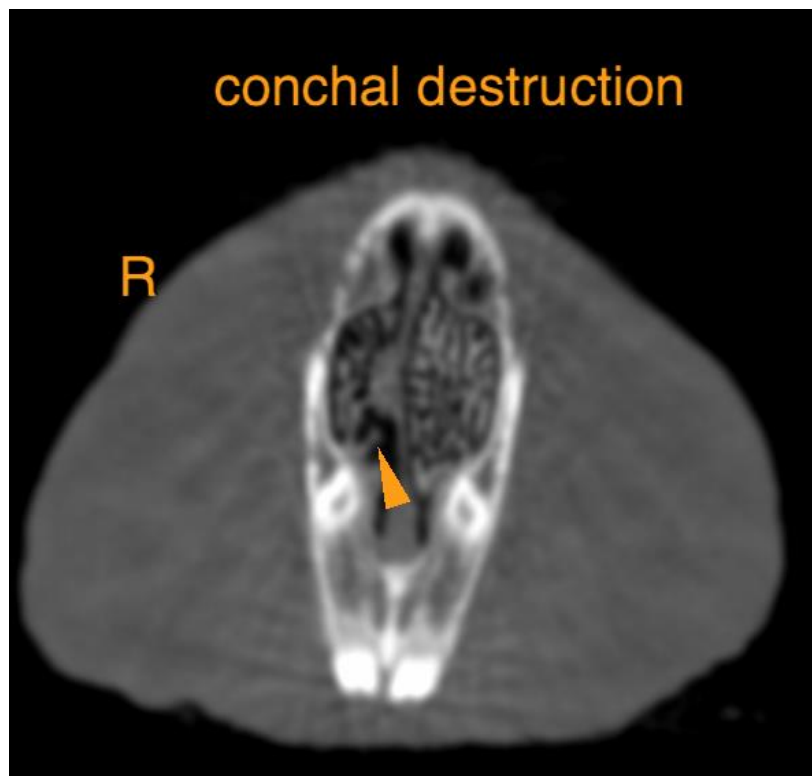
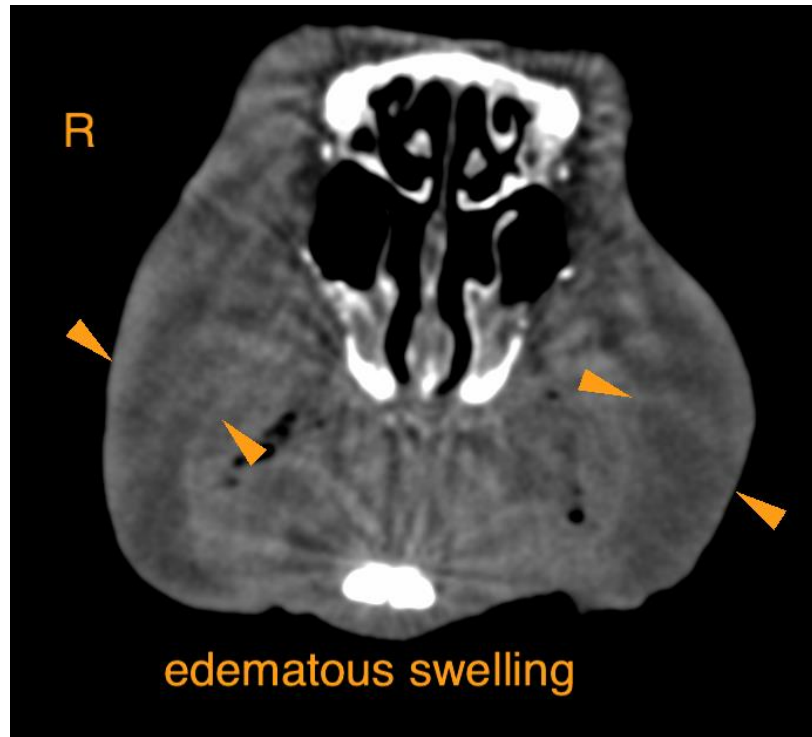
Dr. Joseph
D'Abbraccio

INVOICE

55769

DATE

12-21-22





PATIENT

Skye Castellanos

The information and recommendations provided are based on the images presented by the referring veterinarian/sonographer. No evaluation can be communicated regarding pathology that was not visible in the image/video clips provided.

SPECIES

Lagomorph

Thank you for this referral. If the clinical or image interpretation does not parallel your findings or if I can be of any further assistance please contact me.

BREED

Hotot

Sebastian Schaub, Sebastian Schaub, DVM, Dr. med. vet. DipECVDI
sebast.schaub@gmail.com

SEX

Female Spayed

AGE

7

INTERPRETED BY

Sebastian Schaub, DVM
Dr. med. vet. DipECVDI

HOSPITAL NAME

Catskill Veterinary
Services, PLLC

REFERRING VET

Dr. Joseph
D'Abbraccio

INVOICE

55769

DATE

12-21-22