



**PATIENT**

Bear Neumaier

**PRESENTING CLINICAL SIGNS**

Recheck xrays from 12/5. Patient has been doing better with convenia injections and is taking temaril p.

**SPECIES**

Canine

**RADIOGRAPHIC STUDY OF THE THORAX**

Radiographs of the thorax in three imaging planes are provided for review.

**BREED**

Pomeranian

**RADIOGRAPHIC FINDINGS**

In comparison to the preceding radiographic study, the soft tissue opacification of the left cranial lung lobe is significantly regressive, and the lung parenchyma is aerated.

No additional findings in comparison to the preceding radiographic study.

**SEX**

MN

- Remission of pneumonia left cranial lung lobe

**RADIOGRAPHIC DIAGNOSIS**

**INTERPRETATION OF THE FINDINGS & FURTHER RECOMMENDATIONS**

The radiographic study presents complete remission of the consolidation of the left cranial lung lobe, supporting the diagnosis of pneumonia that is in remission.

**AGE**

13 Years, 9 Months

**INTERPRETED BY**

Sebastian Schaub, DVM  
Dr. med. vet. DipECVDI

**HOSPITAL NAME**

Elizabeth Animal  
Hospital

**REFERRING VET**

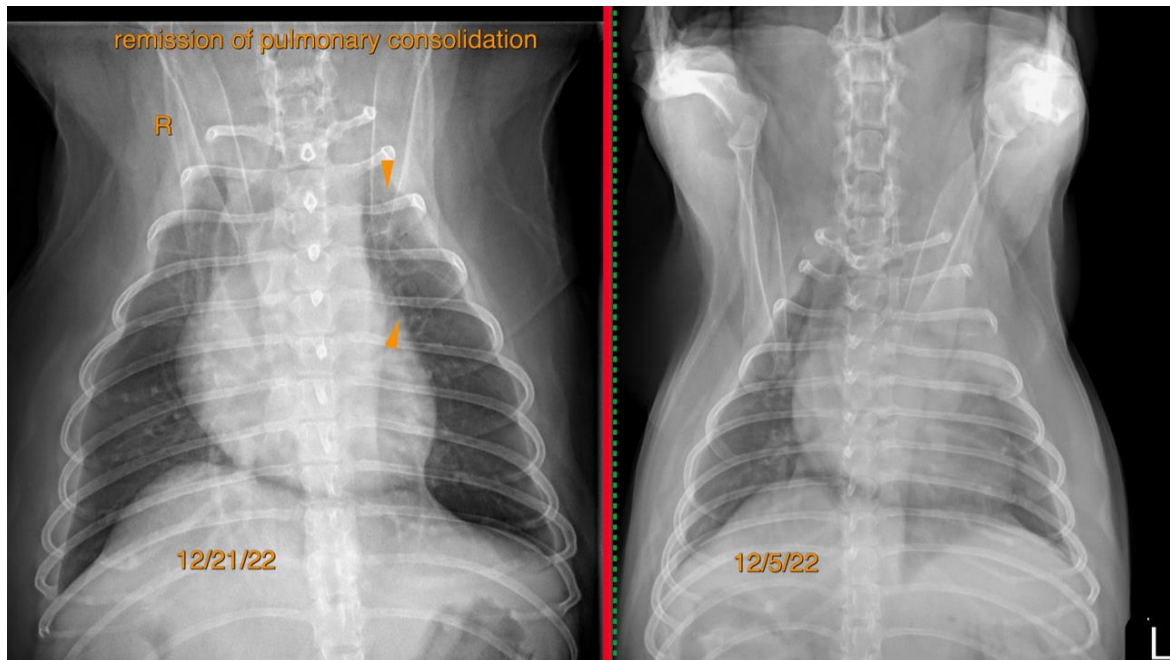
Jennifer Redus, DVM

**INVOICE**

55772

**DATE**

12-21-22





**PATIENT**

Bear Neumaier

The information and recommendations provided are based on the images presented by the referring veterinarian/sonographer. No evaluation can be communicated regarding pathology that was not visible in the image/video clips provided.

**SPECIES**

Canine

Thank you for this referral. If the clinical or image interpretation does not parallel your findings or if I can be of any further assistance please contact me.

**BREED**

Pomeranian

**Sebastian Schaub**, Sebastian Schaub, DVM, Dr. med. vet. DipECVDI  
sebast.schaub@gmail.com

**SEX**

MN

**AGE**

13 Years, 9 Months

**INTERPRETED BY**

Sebastian Schaub, DVM  
Dr. med. vet. DipECVDI

**HOSPITAL NAME**

Elizabeth Animal  
Hospital

**REFERRING VET**

Jennifer Redus, DVM

**INVOICE**

55772

**DATE**

12-21-22