



PATIENT

Rosie Zeiler

PRESENTING CLINICAL SIGNS

Hx of hypoglycemia, ptyalism, enlarged salivary glands, difficulty swallowing -had a similar episode in February w/which resolved on prednisolone and sucralfate Hx of mandibular fracture Abnormal PE/Chem/CBC/UA Results: Normal

SPECIES

Canine

COMPUTED TOMOGRAPHY OF THE SKULL & THORAX

A high resolution pre- and post-contrast CT study of the skull and a post-contrast CT study of the thorax are provided for review.

BREED

Pomeranian

COMPUTED TOMOGRAPHIC FINDINGS

Skull

All teeth but triadan 404 are absent. Advanced atrophy of the alveolar bone in all jaw quadrants is appreciated. Symphysiolysis of the mandible is appreciated. The salivary glands are subjectively prominent.

SEX

FS

The nasal cavity presents the expected aerated spaces between thin & even conchae and turbinates with smooth mucosal lining.

AGE

4

Both temporomandibular joints present congruent joint spaces with even subchondral bone surfaces and are considered within normal limits.

Both tympanic bullae are aerated, the mucosal lining is not seen, the bony wall is smooth and thin. The external ear canals are within normal limits.

INTERPRETED BY

Sebastian Schaub, DVM
Dr. med. vet. DipECVDI

The brain presents no deviation from normal anatomy and symmetry. The brain parenchyma is homogeneous and within normal limits for attenuation and distribution of contrast enhancement. The ventricular system is non-dilated and symmetric. Incomplete ossification of the bregmatic fontanelle is seen.

HOSPITAL NAME

Northeast Veterinary
Referral Hospital

The submandibular and medial retropharyngeal lymph nodes are small and elongated with a normal short-to-long-axis-ratio is < 0.5, the attenuation and contrast enhancement pattern is uniform.

Dorsal angulation of the dens axis is appreciated and there is focal kinking of the dural tube.

Thorax

REFERRING VET

Dr. Runde

The bony and surrounding soft tissue structures are within normal limits.

The sternal, cranial mediastinal and tracheobronchial lymph nodes are small elongated with a normal short-to-long-axis-ratio is < 0.5, the attenuation and contrast enhancement pattern is uniform and considered within normal limits.

INVOICE

55726

The cardiovascular structures including the pulmonary vasculature are within normal limits.

The bronchial tree presents with regular branching and tapers uniformly towards the periphery as expected, the bronchial walls are thin and smooth. The bronchus-to-artery ratio is within normal limits.

DATE

12-20-22

The lung parenchyma presents the expected architecture and attenuation behavior.

Small incidental gas pockets are seen within the esophageal lumen, there is no evidence of



PATIENT abnormal dilation.

Rosie Zeiler

COMPUTED TOMOGRAPHIC DIAGNOSIS

SPECIES

Canine

- Possible mild hypertrophy of the salivary glands
- Multiple absent teeth
- Advanced atrophy of the alveolar bone in all jaw quadrants and history of mandibular fracture and mandibular symphysiolysis
- Normal thorax

BREED

Pomeranian

INTERPRETATION OF THE FINDINGS & FURTHER RECOMMENDATIONS

The CT study presents no specific abnormality, explaining the presenting clinical signs. The prominent salivary glands can be a sequela to sialadenitis or sialadenosis – the latter might be associated with the ptyalism.

SEX

FS

AGE

4

INTERPRETED BY

Sebastian Schaub, DVM
Dr. med. vet. DipECVDI

HOSPITAL NAME

Northeast Veterinary
Referral Hospital

REFERRING VET

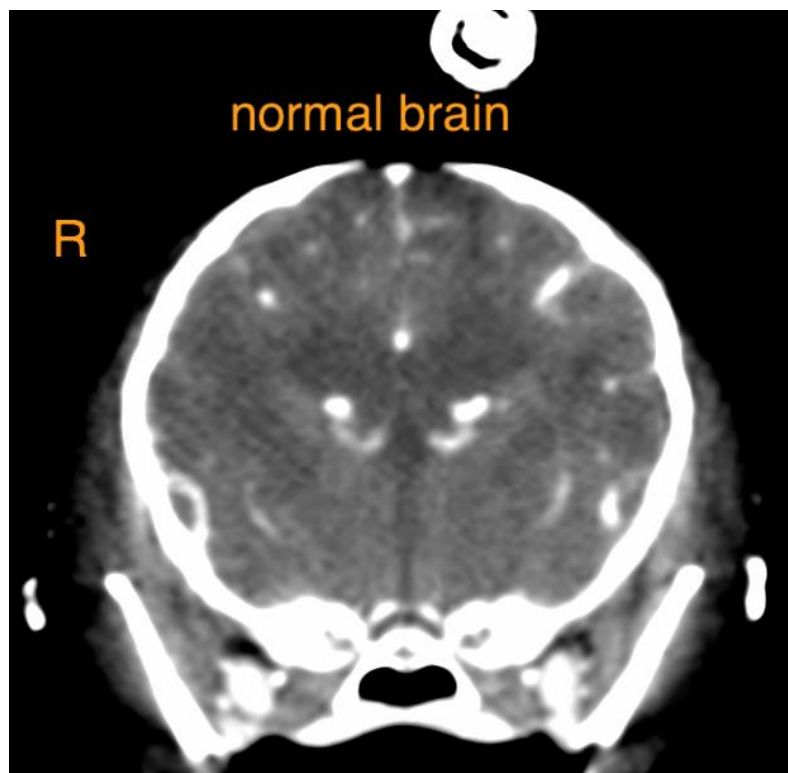
Dr. Runde

INVOICE

55726

DATE

12-20-22





PATIENT

Rosie Zeiler

SPECIES

Canine

BREED

Pomeranian

SEX

FS

AGE

4

INTERPRETED BY

Sebastian Schaub, DVM
Dr. med. vet. DipECVDI

HOSPITAL NAME

Northeast Veterinary
Referral Hospital

REFERRING VET

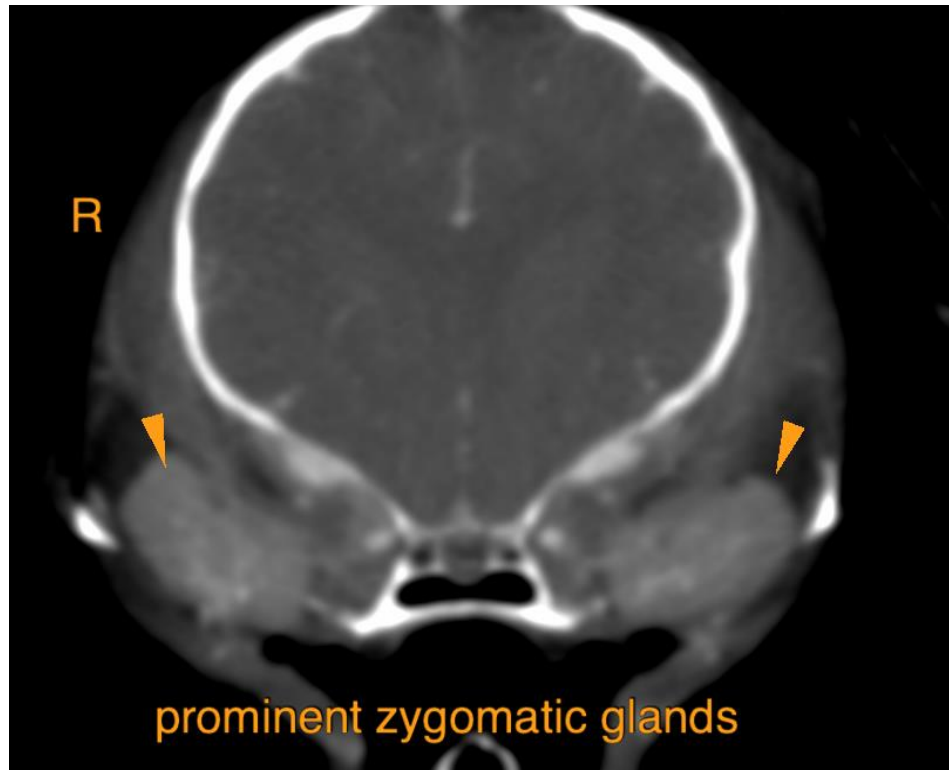
Dr. Runde

INVOICE

55726

DATE

12-20-22



The information and recommendations provided are based on the images presented by the referring veterinarian/sonographer. No evaluation can be communicated regarding pathology that was not visible in the image/video clips provided.

Thank you for this referral. If the clinical or image interpretation does not parallel your findings or if I can be of any further assistance please contact me.

Sebastian Schaub, Sebastian Schaub, DVM, Dr. med. vet. DipECVDI
sebast.schaub@gmail.com