



PATIENT

Max Geldeard

PRESENTING CLINICAL SIGNS

Intermittent lameness LEFT fore, gait analysis suspect elbow not shoulder
Abnormal PE/Chem/CBC/UA Results: NAD

SPECIES

Canine

COMPUTED TOMOGRAPHY OF THE LEFT ELBOW JOINT

A high resolution plain CT study of the left elbow joint is provided for review.

BREED

Labrador

COMPUTED TOMOGRAPHIC FINDINGS

The periarticular bones of the left elbow joint present mild osteophyte new bone formation. The tip of the medial coronoid process of the right elbow joint has a decreased density and presents a prominent concave depression of the subchondral bone. The joint space of the left elbow joint is mildly incongruent.

SEX

Male Neutered

COMPUTED TOMOGRAPHIC DIAGNOSIS

- Coronoid disease left elbow joint
- Mild incongruity left elbow joint
- Degenerative osteoarthritis left elbow joint

AGE

3 Years

INTERPRETATION OF THE FINDINGS & FURTHER RECOMMENDATIONS

The findings are consistent with disease of the medial coronoid process of the left elbow joint with a potential cartilaginous fragment and secondary degenerative joint disease of the left elbow joint. Arthroscopy would be ideal for revision of the left elbow joint.

INTERPRETED BY

Sebastian Schaub, DVM
Dr. med. vet. DipECVDI

HOSPITAL NAME

Myerscough
Veterinary Group

REFERRING VET

M Chowdhury

INVOICE

55706

DATE

12-20-22



PATIENT

Max Geldeard

SPECIES

Canine

BREED

Labrador

SEX

Male Neutered

AGE

3 Years

INTERPRETED BY

Sebastian Schaub, DVM
Dr. med. vet. DipECVDI

HOSPITAL NAME

Myerscough
Veterinary Group

REFERRING VET

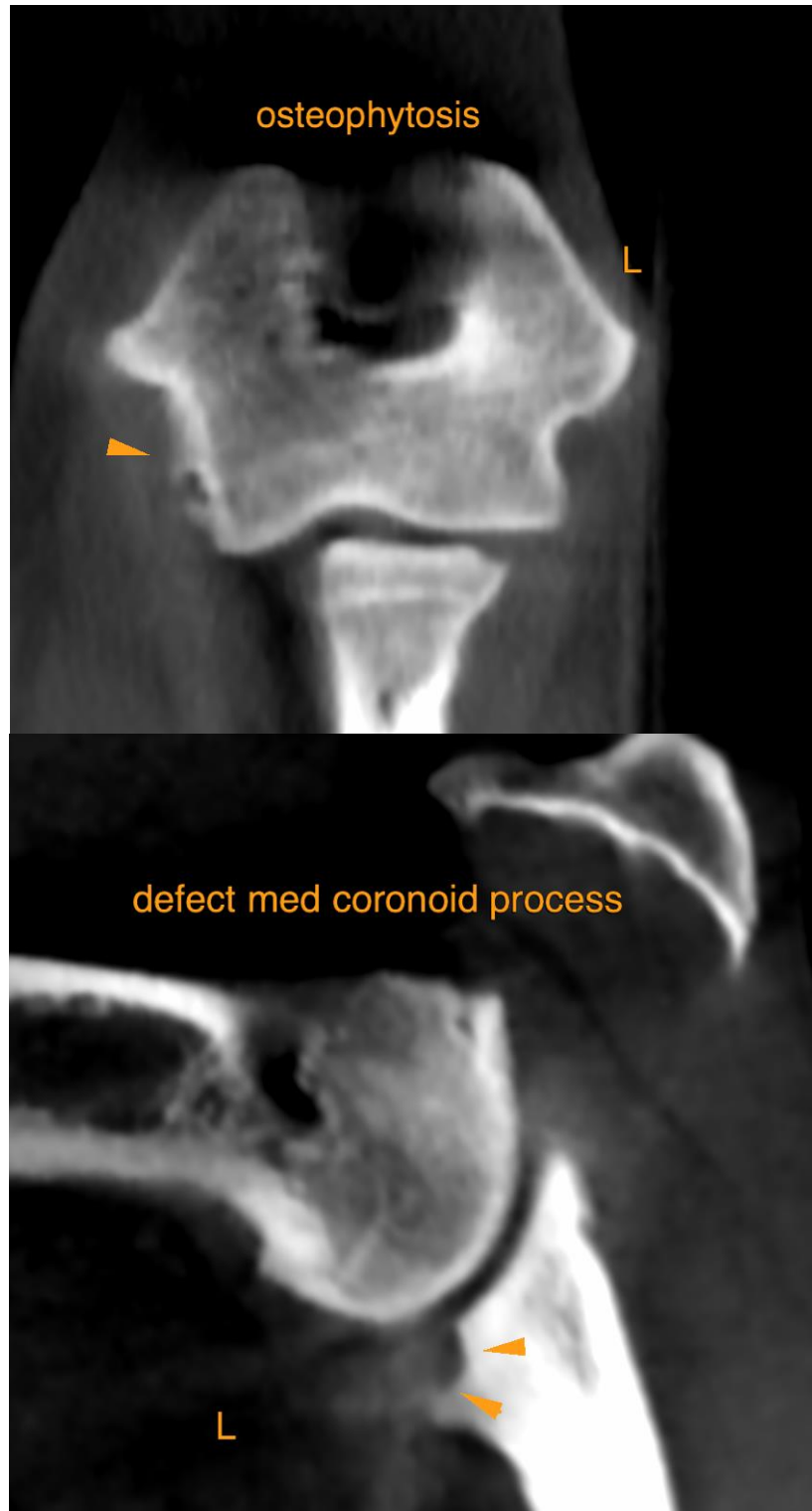
M Chowdhury

INVOICE

55706

DATE

12-20-22





PATIENT

Max Geldeard

SPECIES

Canine

BREED

Labrador

SEX

Male Neutered

AGE

3 Years

INTERPRETED BY

Sebastian Schaub, DVM
Dr. med. vet. DipECVDI

HOSPITAL NAME

Myerscough
Veterinary Group

REFERRING VET

M Chowdhury

INVOICE

55706

DATE

12-20-22

The information and recommendations provided are based on the images presented by the referring veterinarian/sonographer. No evaluation can be communicated regarding pathology that was not visible in the image/video clips provided.

Thank you for this referral. If the clinical or image interpretation does not parallel your findings or if I can be of any further assistance please contact me.

Sebastian Schaub, Sebastian Schaub, DVM, Dr. med. vet. DipECVDI
sebast.schaub@gmail.com