



PATIENT

Buddy Ramadei

PRESENTING CLINICAL SIGNS

Hx of diaphragmatic hernia. O notes wheezing episodes. Started before Thanksgiving, then resolved. Started up again yesterday. P is doing fine otherwise.

SPECIES

Feline

RADIOGRAPHIC STUDY OF THE THORAX

Radiographs of the thorax in three imaging planes are provided for review.

BREED

DSH

The cranial abdomen appears empty.

SEX

Neutered Male

The ventral aspect of the diaphragm cannot be delineated, and gas filled tubular structures as well as soft tissue opaque structures (suspect parts of the liver and spleen) are bulging into the caudoventral aspect of the pleural cavity bilaterally. The caudal lung lobes are deviated dorsally have a decreased volume. The lung parenchyma presents the expected architecture with a generalized mild increased radiopacity of the lung parenchyma. The cardiac silhouette is in a relative cranial position and the caudal border is ill-defined.

AGE

10 Years, 5 Months

In the subcutaneous tissue at the lateral aspect of the right scapula, multiple small gas inclusions are appreciated – likely due to preceding subcutaneous injection.

The extrathoracic soft tissues present homogeneous without abnormalities.

The heart appears to be of normal size and shape.

INTERPRETED BY

Sebastian Schaub, DVM
Dr. med. vet. DipECVDI

RADIOGRAPHIC DIAGNOSIS

- History of diaphragmatic hernia with prolapse of small intestinal loops, parts of the liver and the spleen

HOSPITAL NAME

The Pet Hospital of
Stratford

INTERPRETATION OF THE FINDINGS & FURTHER RECOMMENDATIONS

The radiographic study is fitting the history of diaphragmatic hernia. No additional abnormalities of the lung field are appreciated, but evaluation is limited due to the diaphragmatic hernia. Rule out that the diaphragmatic hernia is the cause for the presenting clinical signs. Surgical management of the diaphragmatic hernia is the therapy of choice; there is latent risk for herniation of the stomach that can gas up and result in a clinical emergency.

REFERRING VET

Dr. Claudia Giuliani

INVOICE

55719

DATE

12-20-22



PATIENT

Buddy Ramadei

SPECIES

Feline

BREED

DSH

SEX

Neutered Male

AGE

10 Years, 5 Months

INTERPRETED BY

Sebastian Schaub, DVM
Dr. med. vet. DipECVDI

HOSPITAL NAME

The Pet Hospital of
Stratford

REFERRING VET

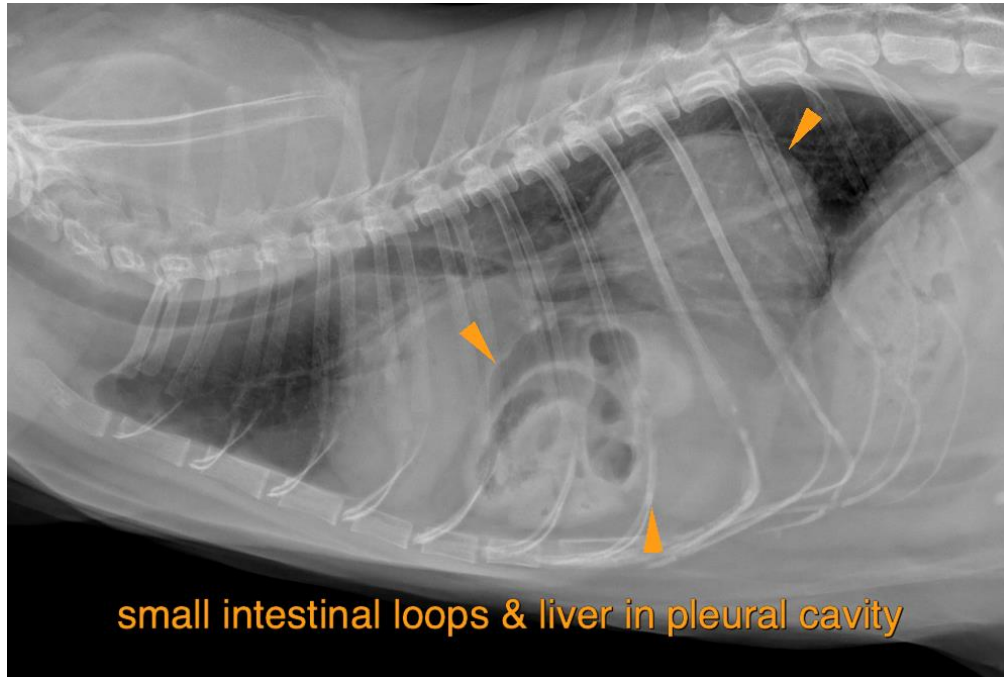
Dr. Claudia Giuliani

INVOICE

55719

DATE

12-20-22



The information and recommendations provided are based on the images presented by the referring veterinarian/sonographer. No evaluation can be communicated regarding pathology that was not visible in the image/video clips provided.

Thank you for this referral. If the clinical or image interpretation does not parallel your findings or if I can be of any further assistance please contact me.

Sebastian Schaub, Sebastian Schaub, DVM, Dr. med. vet. DipECVDI
sebast.schaub@gmail.com