

**PATIENT**

Hugo Musgrave

**PRESENTING CLINICAL SIGNS**

Patient presents for emergent dental evaluation with COHAT. A survey CT of the skull with emphasis on the dental arcade is submitted for review.

**SPECIES**

Canine

**COMPUTED TOMOGRAPHY OF THE SKULL**

A high resolution plain CT study of the skull is provided for review.

**BREED**

Chihuahua

**COMPUTED TOMOGRAPHIC FINDINGS**

The tooth elements 101, 102, 104-106, 202-204, 206, 301, 302, 304, 309-311, 401-403, 410 and 411 are absent. There is a defect of the alveolar bone level with absent 104, perforating the nasal cavity; focal conchal destruction is seen. The defect of the alveolar bone level with absent 104 is covered by gingiva. Triadan 103, 107-110, 208-210, 404 and 409 present a moderate widening of the periodontal space. The remaining teeth present evidence of mild to moderate periodontal disease.

**SEX**

M

Both temporomandibular joints present congruent joint spaces with even subchondral bone surfaces and are considered within normal limits.

**AGE**

~9 Years

Both tympanic bullae are aerated, the mucosal lining is not seen, the bony wall is smooth and thin. The external ear canals are within normal limits.

**INTERPRETED BY**

Sebastian Schaub, DVM  
Dr. med. vet. DipECVDI

**COMPUTED TOMOGRAPHIC DIAGNOSIS**

- Significant periodontal disease 103, 107-110, 208-210, 404 and 409
- Oronasal fistula level with absent triadan 104 and history of preceding odontogenic destructive rhinitis
- Generalized periodontal disease of the remaining teeth
- Multiple absent teeth, see above

**HOSPITAL NAME**

South Bay Animal  
Hospital

**INTERPRETATION OF THE FINDINGS & FURTHER RECOMMENDATIONS**

The findings are consistent with generalized advanced periodontal disease of multiple teeth. A complete dental workup has already performed, with extraction of the affected dental elements.

**REFERRING VET**

Ravinder Atwal, DVM,  
CCRP

**INVOICE**

12-20-21

**DATE**



**PATIENT**

Hugo Musgrave

**SPECIES**

Canine

**BREED**

Chihuahua

**SEX**

M

**AGE**

~9 Years

**INTERPRETED BY**

Sebastian Schaub, DVM  
Dr. med. vet. DipECVDI

**HOSPITAL NAME**

South Bay Animal  
Hospital

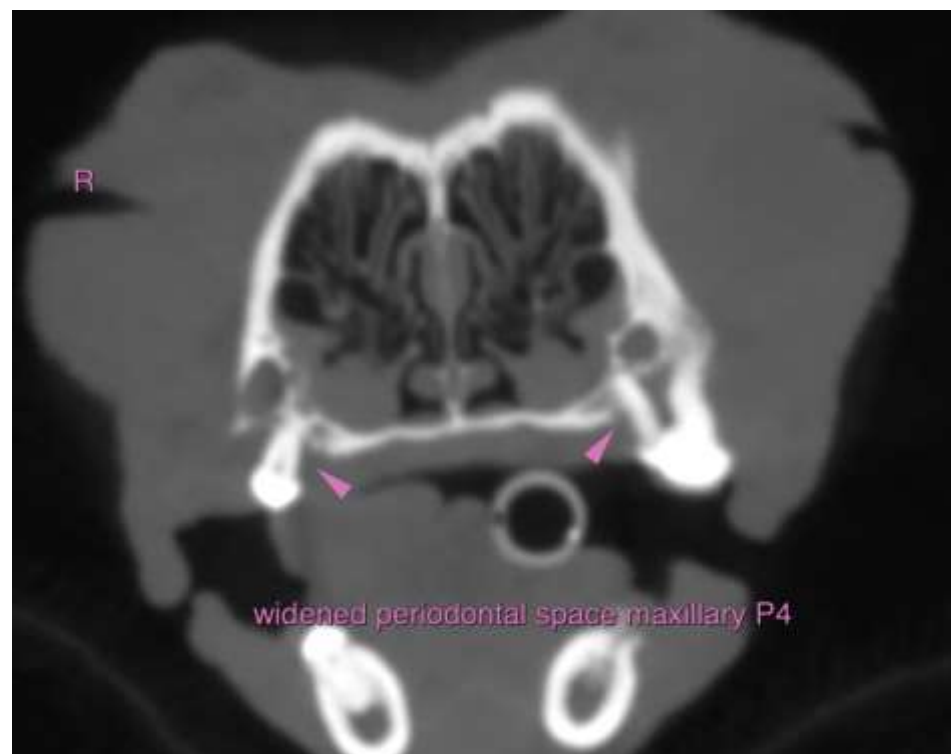
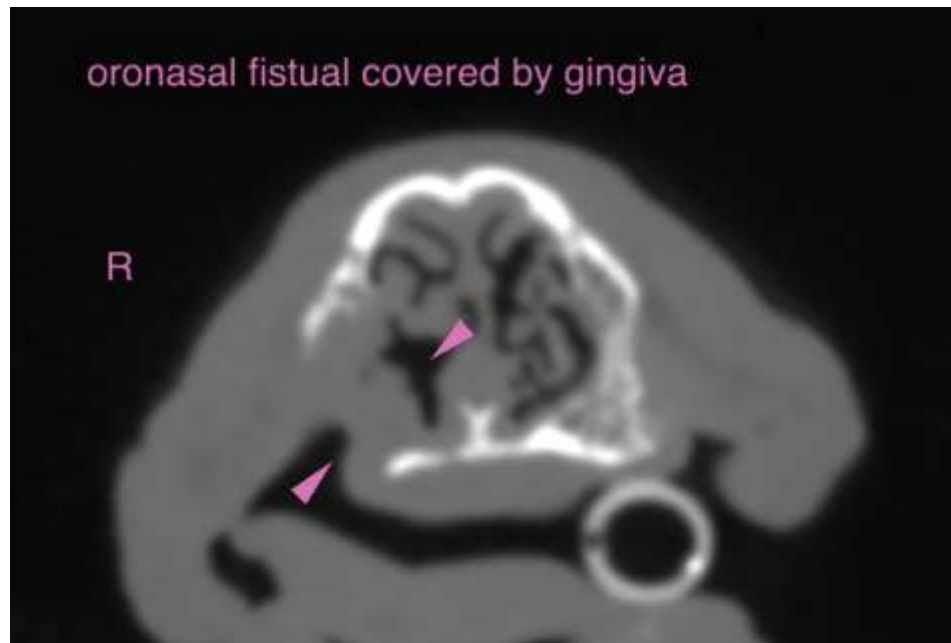**REFERRING VET**

Ravinder Atwal, DVM,  
CCRP

**INVOICE**

12-20-21

**DATE**





**PATIENT**

Hugo Musgrave

The information and recommendations provided are based on the images presented by the referring veterinarian. No evaluation can be communicated regarding pathology that was not visible in the image/video clips provided.

**SPECIES**

Canine

Thank you for this referral. If the clinical or image interpretation does not parallel your findings or if I can be of any further assistance please contact me.

**Sebastian Schaub**, Sebastian Schaub, DVM, Dr. med. vet. DipECVDI  
sebast.schaub@gmail.com

**BREED**

Chihuahua

**SEX**

M

**AGE**

~9 Years

**INTERPRETED BY**

Sebastian Schaub, DVM  
Dr. med. vet. DipECVDI

**HOSPITAL NAME**

South Bay Animal  
Hospital

**REFERRING VET**

Ravinder Atwal, DVM,  
CCRP

**INVOICE**

12-20-21

**DATE**