



## PATIENT

Emma  
O`Connell/Doerr

## SPECIES

Canine

## BREED

Pitbull Mix

## SEX

FS

## AGE

10Y

## WEIGHT

27.8kg

## INTERPRETED BY

Sebastian Schaub, DVM  
Dr. med. vet.  
DipECVDI

## IMAGING PERFORMED BY

Dr.Van Nieuwal

## HOSPITAL NAME

Animal Emergency  
Hospital Volusia

## REFERRING VET

Dr.Van Nieuwal

## INVOICE

72830

## DATE

12-2-25

## PRESENTING CLINICAL SIGNS

Patient presented for evaluation after Owner states that patient has had hacking cough for about 1-2 days. Owner states it sounds like the patient is trying to clear her throat. Cough seemed to intensify last night and patient coughed out small amount of mucous this morning. Owner also stated that the patient had a clear runny nose. Patient has been hacking so hard it is causing patient to vomit small amounts of bile. Patient has history of liver elevations since she was a puppy, on Denamarin. Abnormal PE/Chem/CBC/UA Results: CBC- WNL Chemistry- BUN 7.3, GLOB 4.1, ALP 452 EPOC- BUN 6 Radiographic CONCLUSION: Soft tissue opacity in the region of the middle tracheobronchial lymph node. Middle tracheobronchial lymphadenomegaly is suspected. Differentials include fungal disease, granulomatous disease, round cell neoplasia, or metastatic disease. A medially located primary mass of one of the caudal lung lobes is unlikely. CT examination may be considered for further evaluation. Small amount of granular mineral opaque gastric material. This material is nonobstructive but may be indicative of dietary indiscretion. This report was finalized by Ashley Yanchik, VMD, DACVR, DACVR-EDI

## COMPUTED TOMOGRAPHY OF THE THORAX AND ABDOMEN

A high resolution pre- and post-contrast CT study of the abdomen and a post-contrast CT study of the thorax is provided for review.

## COMPUTED TOMOGRAPHIC FINDINGS

### Thorax

The bony and surrounding soft tissue structures are within normal limits.

The tracheobronchial lymph nodes are prominent.

The cardiovascular structures including the pulmonary vasculature are within normal limits.

In the hilar region of the right cranial lung lobe, an ill-defined, uniform soft tissue attenuating and contrast enhancing mass is seen, encompassing the right principal bronchus and first degree bronchi of the right middle & caudal lung lobe in the hilar region; the affected bronchi are distorted and compressed. The bronchial tree of the right cranial lung lobe and right middle lung lobe present a smooth thickened wall.

Small incidental gas pockets are seen within the esophageal lumen; there is no evidence of abnormal dilation.

### Abdomen

The serosal fat presents normal attenuation behavior. There is no evidence of peritoneal effusion or peritonitis.

Both kidneys present within normal limits for size, shape and organ architecture. After contrast administration, a bilaterally symmetric and uniform nephro- and pyelogram is noted.

The adrenal glands are within normal limits for size, shape and organ architecture.

Both liver and spleen present with normal shape, even surface, uniformly attenuating parenchyma and homogeneous contrast enhancement, unremarkable.

The pancreas is evenly contoured; the pancreatic parenchyma is homogeneous and presents uniform contrast enhancement.



## PATIENT

Emma  
O`Connell/Doerr

## SPECIES

Canine

## BREED

Pitbull Mix

## SEX

FS

## AGE

10Y

## WEIGHT

27.8kg

## INTERPRETED BY

Sebastian Schaub, DVM  
Dr. med. vet.  
DipECVDI

## IMAGING PERFORMED BY

Dr. Van Nieuwal

## HOSPITAL NAME

Animal Emergency  
Hospital Volusia

## REFERRING VET

Dr. Van Nieuwal

## INVOICE

72830

## DATE

12-2-25

The position, delineation, wall and content of the gastrointestinal tract are considered within normal limits throughout.

A defect is seen in the left lamina T13/L1 to L1/L2. The intervertebral discs L1/L2 is protruding into the vertebral canal, occupying approximately  $\leq 15\%$  of the cross-sectional area of the vertebral canal at the same level. The intervertebral discs along the lumbar spine present variable degree of central mineralization.

The vertebral endplates of the lumbosacral junction present mild spondylosis formation.

## COMPUTED TOMOGRAPHIC DIAGNOSIS

- Hilar soft tissue mass right cranial lung lobe with involvement of the right principal bronchus, right middle and caudal lung lobe
- Bronchial pattern right lung lobes
- Lymphadenopathy tracheobronchial lymph nodes
- History of hemilaminectomy T13/L1 to L1/L2
- Intervertebral disc herniation L1/L2 without compressive myelopathy
- Spondylosis deformans

## INTERPRETATION OF THE FINDINGS & FURTHER RECOMMENDATIONS

The pulmonary soft tissue mass is most consistent with primary bronchogenic pulmonary neoplasia – carcinoma with spread along the bronchial tree and metastatic spread to the regional lymph nodes is most likely. Theoretically granulomatous mycotic lung disease is a differential, but I consider the odds low. Bronchoscopy including sampling may be used for confirmation. Surgical management is considered not feasible here.



## PATIENT

Emma  
O`Connell/Doerr

## SPECIES

Canine

## BREED

Pitbull Mix

## SEX

FS

## AGE

10Y

## WEIGHT

27.8kg

## INTERPRETED BY

Sebastian Schaub, DVM  
Dr. med. vet.  
DipECVDI

## IMAGING PERFORMED BY

Dr. Van Nieuwal

## HOSPITAL NAME

Animal Emergency  
Hospital Volusia

## REFERRING VET

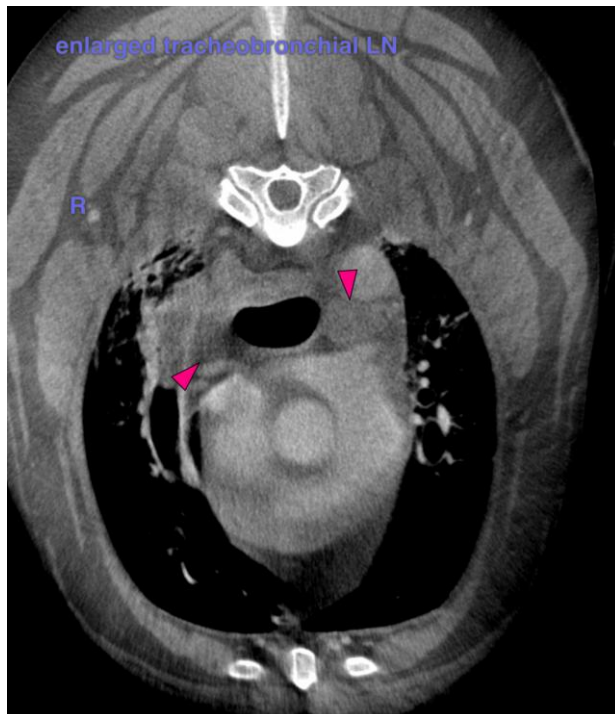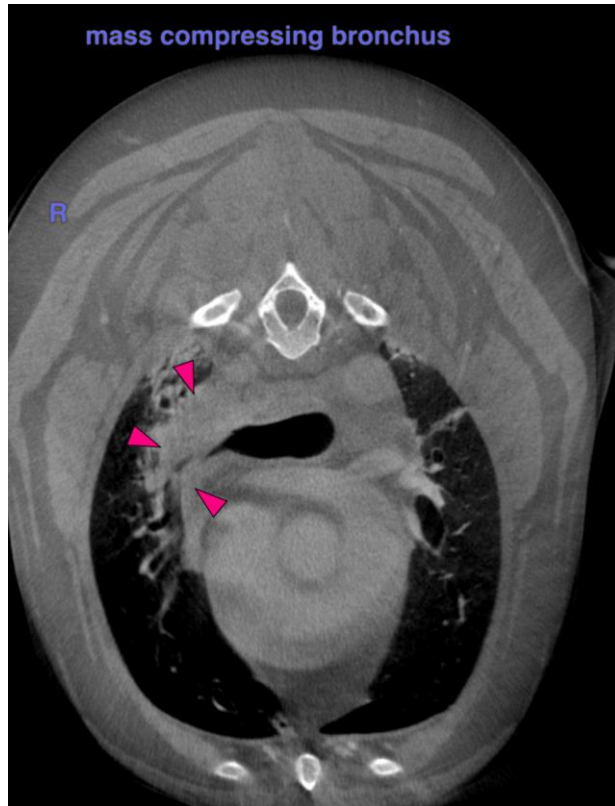
Dr. Van Nieuwal

## INVOICE

72830

## DATE

12-2-25





## PATIENT

Emma  
O`Connell/Doerr

## SPECIES

Canine

## BREED

Pitbull Mix

## SEX

FS

## AGE

10Y

## WEIGHT

27.8kg

## INTERPRETED BY

Sebastian Schaub, DVM  
Dr. med. vet.  
DipECVDI

## IMAGING PERFORMED BY

Dr.Van Nieuwal

## HOSPITAL NAME

Animal Emergency  
Hospital Volusia

## REFERRING VET

Dr.Van Nieuwal

## INVOICE

72830

## DATE

12-2-25

The information and recommendations provided are based on the images presented by the referring veterinarian/sonographer. No evaluation can be communicated regarding pathology that was not visible in the image/video clips provided.

Thank you for this referral. If the clinical or image interpretation does not parallel your findings or if I can be of any further assistance please contact me.

**Sebastian Schaub**, Sebastian Schaub, DVM, Dr. med. vet. DipECVDI  
[info@sonopath.com](mailto:info@sonopath.com)