



PATIENT PRESENTING CLINICAL SIGNS

Shadow Adopt a Dog Rescue
 History: Patient presented for evaluation of a mass on the right axillary region. Owner stated that the mass is progressively getting bigger. CT scan of the right axillary and thorax regions mass removal ONLY on right axillary region based on the CT results.

SPECIES COMPUTED TOMOGRAPHIC STUDY OF THE THORAX

Canine A high-resolution plain CT study of the thorax is provided for review.

BREED COMPUTED TOMOGRAPHIC FINDINGS

Labrador
 Extending from the caudal aspect of the right axillary region caudally along the right thoracic wall up to the 10th right intercostal space, a well-defined, ovoid shaped, uniform fat attenuating mass is seen, demarcated by a thin, soft tissue attenuating capsule; the mass is measuring 21 x 11 cm in height and width.

SEX

Neutered Male
 In the caudal aspect of the left axillary region, a well-defined ovoid shaped, uniform fat attenuating mass, measuring 7.6 x 3.8 x 10 cm is appreciated.

AGE

9 Years
 Multiple small subcutaneous and intermuscular lipomas are appreciated along the thorax. The sternal, cranial mediastinal and tracheobronchial lymph nodes are small elongated with a normal short-to-long-axis-ratio is < 0.5, the attenuation is uniform.

INTERPRETED BY

The cardiovascular structures including the pulmonary vasculature are within normal limits.

Sebastian Schaub,
 DVM Dr. med. vet.
 DipECVDI

The bronchial tree presents with regular branching and tapers uniformly towards the periphery as expected, the bronchial walls are thin and smooth. The bronchus-to-artery ratio is within normal limits.

HOSPITAL NAME

The lung parenchyma presents the expected architecture and attenuation behavior, but dystelectasis of the ventral dependent aspects of the lung parenchyma.

Animal Surgical
 Center

Small incidental gas pockets are seen within the esophageal lumen, there is no evidence of abnormal dilation.

COMPUTED TOMOGRAPHIC DIAGNOSIS

REFERRING VET

- Large lipoma right thoracic wall
- Lipoma left axillary region
- Multiple smaller lipomas along the axillary region and thoracic wall
- No evidence of pulmonary metastatic spread

Hudson Highlands VG

INVOICE

18975

INTERPRETATION OF THE FINDINGS & FURTHER RECOMMENDATIONS

DATE

12/2/22



PATIENT

Shadow Adopt a Dog
Rescue

The CT study is consistent with a large lipoma extending from the right axillary region along the thoracic wall – complete surgical excision of the mass is considered feasible. There are multiple additional lipomas along the thoracic wall with the largest being located in the caudal aspect of the left axillary region.

SPECIES

Canine

BREED

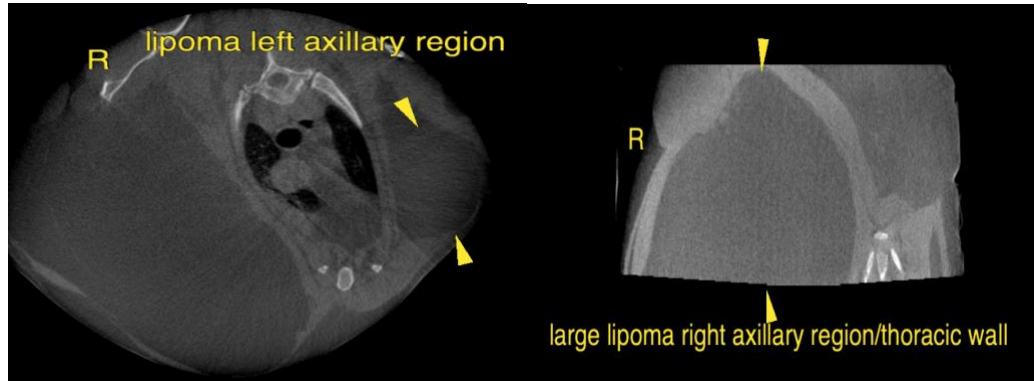
Labrador

SEX

Neutered Male

AGE

9 Years



The information and recommendations provided are based on the images presented by the referring veterinarian/sonographer. No evaluation can be communicated regarding pathology that was not visible in the image/video clips provided.

Thank you for this referral. If the clinical or image interpretation does not parallel your findings or if I can be of any further assistance please contact me.

INTERPRETED BY

Sebastian Schaub,
DVM Dr. med. vet.
DipECVDI

Sebastian Schaub, Sebastian Schaub, DVM, Dr. med. vet. DipECVDI
sebast.schaub@gmail.com

HOSPITAL NAME

Animal Surgical
Center

REFERRING VET

Hudson Highlands VG

INVOICE

18975

DATE

12/2/22