



**PATIENT PRESENTING CLINICAL SIGNS**

Sofi Boyd Hx of elevated liver enzymes prompted an ultrasound examination. A mass was noted on the spleen and liver nodule.

**SPECIES**

Canine

**BREED**

Yorkshire Terrier

**SEX**

Female Spayed

Abnormal PE/Chem/CBC/UA Results: Findings Multiple sonographic images of the abdomen are reviewed, dated November 10, 2021. The spleen has a 4 cm heterogeneous partially cavitated mass along the cranial margin, and a separate 3 cm mass more caudally. The kidneys are ageappropriate at 3-3.5 cm in length. The adrenal glands are normal up to 5 mm. The stomach contains some gas. The liver has a 4 cm hyperechoic mass near the diaphragm which is mostly homogeneous. This distorts the gallbladder. The gallbladder is otherwise normal. The small intestine and colon are normal in size, content, and wall layering. The urinary bladder is unremarkable. The pancreas is normal. No peritoneal effusion or lymphadenopathy is present. Conclusion 1. Splenic masses. Malignancy is considered such as sarcoma although benign etiologies are not completely excluded. Histopathology is recommended for further characterization. 2. The liver mass may be a well-differentiated carcinoma or adenoma. Unfortunately this is unlikely to be amenable to ultrasound-guided sampling. Computed tomography could be useful if desired. Read By: Layla Shaikh, VMD, DACVR

**COMPUTED TOMOGRAPHY OF THE THORAX AND ABDOMEN**

**AGE**

10 Years

A high resolution pre- and post-contrast CT study of the abdomen and a post-contrast CT study of the thorax are provided for review.

**INTERPRETED BY**

Sebastian Schaub, DVM  
Dr. med. vet. DipECVDI

Thorax

The bony and surrounding soft tissue structures are within normal limits.

**HOSPITAL NAME**

Mobile Pet Imaging

The sternal, cranial mediastinal and tracheobronchial lymph nodes are small elongated with a normal short-to-long-axis-ratio is < 0.5, the attenuation and contrast enhancement pattern is uniform and considered within normal limits.

The cardiovascular structures including the pulmonary vasculature are within normal limits.

**REFERRING VET**

Meaux

The bronchial tree presents with regular branching and tapers uniformly towards the periphery as expected, the bronchial walls are thin and smooth. The bronchus-to-artery ratio is within normal limits.

The lung parenchyma presents the expected architecture and attenuation behavior.

**INVOICE**

48750

Small incidental gas pockets are seen within the esophageal lumen, there is no evidence of abnormal dilation.

**DATE**

12-2-21

Abdomen

The serosal fat presents normal attenuation behavior. There is no evidence of peritoneal effusion or peritonitis.

Both kidneys present within normal limits for size, shape and organ architecture. After contrast administration a bilaterally symmetric and uniform nephro- and pyelogram is noted.

**PATIENT**

Sofi Boyd

The adrenal glands are within normal limits for size, shape and organ architecture.

**SPECIES**

Canine

Generalized irregular macronodular enlargement of the spleen is seen, presenting a marked heterogeneous contrast enhancement pattern with regions of strong contrast enhancement and regions without contrast enhancement – the cranial extremity of the spleen presents a well-defined zone without contrast enhancement.

**BREED**

Yorkshire Terrier

The hepatic volume is moderately increased and multifocal throughout the hepatic parenchyma, post contrast hypoattenuating parenchymal filling defects with central/eccentric contrast enhancing focus are present.

**SEX**

Female Spayed

The pancreas is evenly contoured, the pancreatic parenchyma is homogeneous and presents uniform contrast enhancement.

The position, delineation, wall and content of the gastrointestinal tract are considered within normal limits throughout.

The bony and surrounding soft tissue structures reveal no abnormalities.

**COMPUTED TOMOGRAPHIC DIAGNOSIS****AGE**

10 Years

- Macronodular enlargement of the spleen with zones of splenic infarction
- Post contrast hypoattenuating lesions throughout the hepatic parenchyma
- Hepatomegaly
- Structural normal thorax, no evidence of pulmonary metastatic disease

**INTERPRETED BY**

Sebastian Schaub, DVM  
Dr. med. vet. DipECVDI

**INTERPRETATION OF THE FINDINGS & FURTHER RECOMMENDATIONS****HOSPITAL NAME**

Mobile Pet Imaging

The findings are compatible with splenic neoplastic transformation and likely paraneoplastic regions of splenic infarction. Potentials are hemangiosarcoma, undifferentiated sarcoma, round cell tumor. Splenectomy would be the therapy of choice.

The liver presents multiple post contrast hypoattenuating lesions with a contrast enhancing focus – ‘target-lesion’ – concerning for hepatic neoplasia.

**REFERRING VET**

Meaux

**INVOICE**

48750

**DATE**

12-2-21



**PATIENT**

Sofi Boyd

**SPECIES**

Canine

**BREED**

Yorkshire Terrier

**SEX**

Female Spayed

**AGE**

10 Years

**INTERPRETED BY**

Sebastian Schaub, DVM  
Dr. med. vet. DipECVDI

**HOSPITAL NAME**

Mobile Pet Imaging

**REFERRING VET**

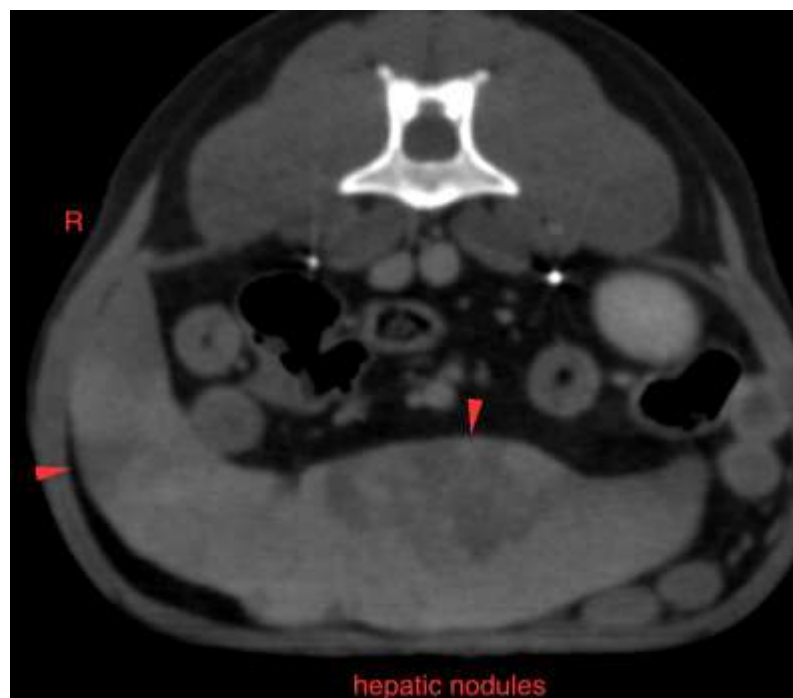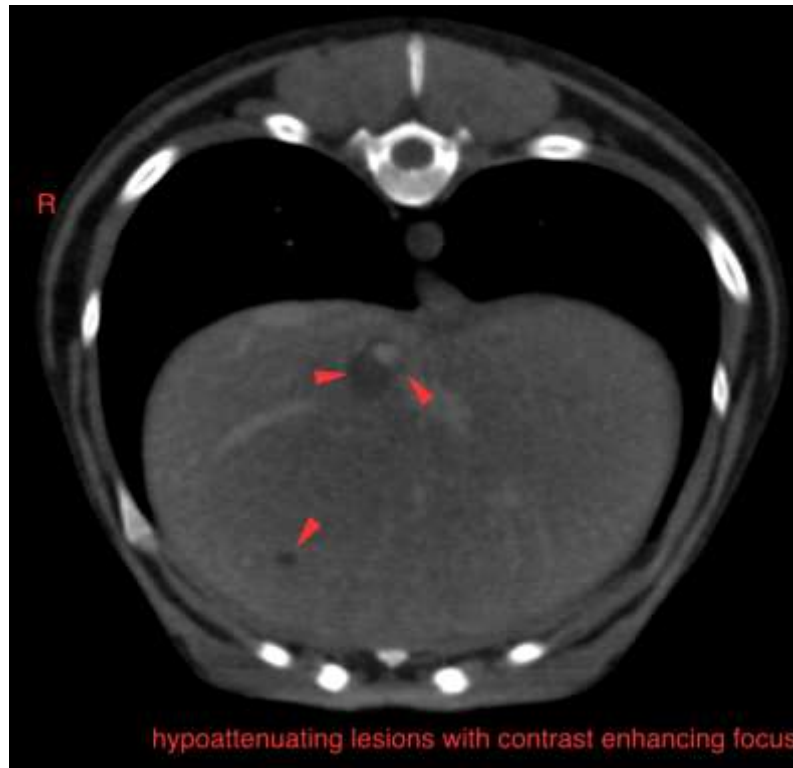
Meaux

**INVOICE**

48750

**DATE**

12-2-21





**PATIENT**

Sofi Boyd

**SPECIES**

Canine

**BREED**

Yorkshire Terrier

**SEX**

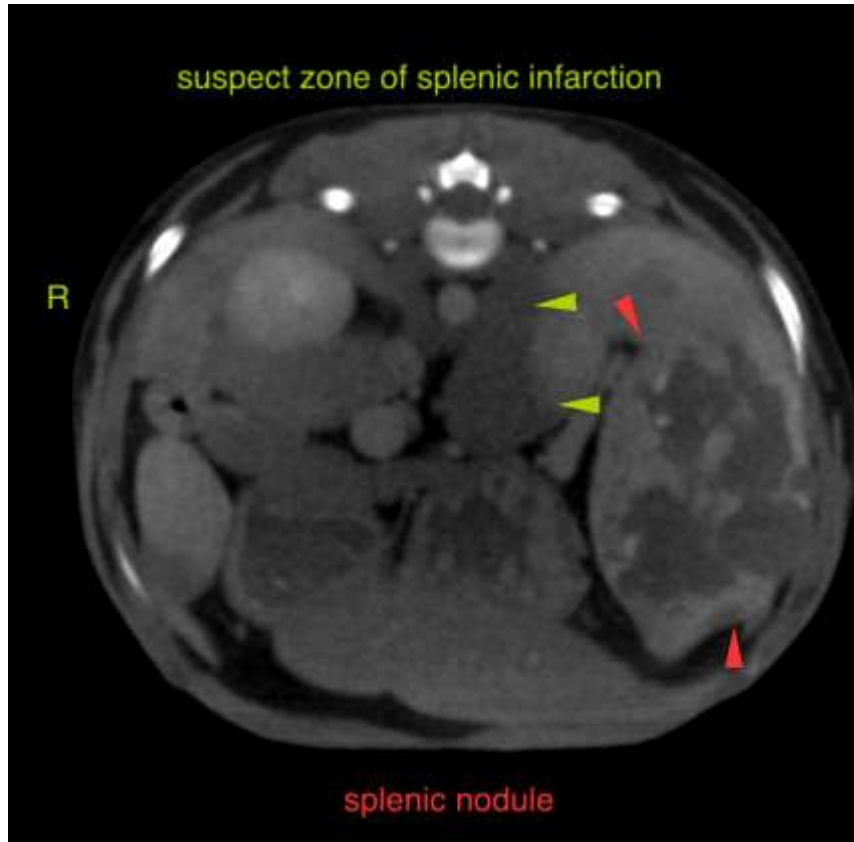
Female Spayed

**AGE**

10 Years

**INTERPRETED BY**

Sebastian Schaub, DVM  
Dr. med. vet. DipECVDI



**HOSPITAL NAME**

Mobile Pet Imaging

**REFERRING VET**

Meaux

**INVOICE**

48750

**DATE**

12-2-21

The information and recommendations provided are based on the images presented by the referring veterinarian. No evaluation can be communicated regarding pathology that was not visible in the image/video clips provided.

Thank you for this referral. If the clinical or image interpretation does not parallel your findings or if I can be of any further assistance please contact me.

**Sebastian Schaub**, Sebastian Schaub, DVM, Dr. med. vet. DipECVDI  
sebast.schaub@gmail.com