



PATIENT

Carly Fishman

PRESENTING CLINICAL SIGNS

Hx of enlarged submand salivary gland. Previously diagnosed w/ chronic sialoadenitis w/o evidence of neoplasia. Additional Hx of PLE +/- lymphangiectasia. Also Hx of hepatomegaly (suspect from chronic steroid administration). Enlarged golf ball sized salivary gland right subman. Excessive gingival tissue under the tongue bilateral. Few teeth. Pot belly.

SPECIES

Canine

COMPUTED TOMOGRAPHY OF THE SKULL & THORAX

A high resolution pre- and post-contrast CT study of the skull and a post-contrast CT study of the thorax are provided for review.

BREED

Yorkshire Terrier

COMPUTED TOMOGRAPHIC FINDINGS

Skull

SEX

All teeth but triadan 308, 309, 404 and 408 are absent.

Female Spayed

The nasal cavity presents the expected aerated spaces between thin & even conchae and turbinates with smooth mucosal lining.

AGE

12 Years

Both temporomandibular joints present congruent joint spaces with even subchondral bone surfaces and are considered within normal limits.

INTERPRETED BY

Sebastian Schaub, DVM
Dr. med. vet. DipECVDI

Both tympanic bullae are aerated, the mucosal lining is not seen, the bony wall is smooth and thin. The external ear canals are within normal limits.

HOSPITAL NAME

Mobile Pet Imaging

The brain presents no deviation from normal anatomy and symmetry. The brain parenchyma is homogeneous and within normal limits for attenuation and distribution of contrast enhancement. The ventricular system is non-dilated and symmetric.

REFERRING VET

Meaux

Originating from the right mandibullary salivary gland, a peripheral contrast enhancing, and central fluid attenuating mass is visible, extending from the rostradorsal aspect of the right mandibular salivary gland rostromedially, with a thin extension along the lateral surface of the right digastric muscle. Multiple small, mineralized bodies are attached to the medial wall of the cavitary mass of the right mandibular salivary gland. The cavitary mass is measuring approximately 2.4 x 1.8 x 2.9 cm in size.

The left mandibular salivary gland presents small, mineralized body in the rostral aspect, measuring 1.5 mm in size.

INVOICE

48749

The submandibular and medial retropharyngeal lymph nodes are small and elongated with a normal short-to-long-axis-ratio is < 0.5, the attenuation and contrast enhancement pattern is uniform.

DATE

12-2-21

Thorax

The intervertebral disc spaces of the pictured segments of the caudal cervical spine are collapsed and the respective vertebral endplates present moderate spondylosis formation. T6 presents a coarse trabecular pattern with moth eaten osteolytic lesions, walled off by a sclerotic rim.



PATIENT

Carly Fishman

The sternal, cranial mediastinal and tracheobronchial lymph nodes are small elongated with a normal short-to-long-axis-ratio is < 0.5, the attenuation and contrast enhancement pattern is uniform and considered within normal limits.

The cardiovascular structures including the pulmonary vasculature are within normal limits.

SPECIES

Canine

Incidental mild dorsoventral flattening of the left principal bronchus is seen. The bronchial tree presents with regular branching and tapers uniformly towards the periphery as expected, the bronchial walls are thin and smooth. The bronchus-to-artery ratio is within normal limits.

BREED

Yorkshire Terrier

The lung parenchyma presents the expected architecture and attenuation behavior, but small regions of dystelectasis of the caudodorsal aspects of the lung.

Small incidental gas pockets are seen within the esophageal lumen, there is no evidence of abnormal dilation.

SEX

Female Spayed

COMPUTED TOMOGRAPHIC DIAGNOSIS

- Sialocele right mandibular salivary gland with small sialolithiasis
- Small sialoliths left mandibular salivary gland without evidence of obstruction
- Monostotic semi-aggressive osteolytic lesions vertebral body T6
- Chronic discopathy caudal cervical spine
- Multiple absent teeth
- No evidence of pulmonary metastatic disease

AGE

12 Years

INTERPRETATION OF THE FINDINGS & FURTHER RECOMMENDATIONS

The findings are consistent with a sialocele originating from the right mandibular salivary gland/sublingual monostomatic salivary gland. The findings explain the submandibular swelling. Sialoadenectomy is the therapy of choice.

INTERPRETED BY

Sebastian Schaub, DVM
Dr. med. vet. DipECVDI

HOSPITAL NAME

Mobile Pet Imaging

The vertebral body of T6 presents with osteolytic lesions, the finding is equivocal for degenerative osseous cysts/fatty bone marrow replacement or early stage of neoplastic disease – such as osteosarcoma, plasmocytoma, metastasis, other. Bone biopsy can be tried as advanced diagnostic test. Follow up CT study in 1-2month might be considered alternatively to screen if changes are progressive.

REFERRING VET

Meaux

INVOICE

48749

DATE

12-2-21



PATIENT

Carly Fishman

SPECIES

Canine

BREED

Yorkshire Terrier

SEX

Female Spayed

AGE

12 Years

INTERPRETED BY

Sebastian Schaub, DVM
Dr. med. vet. DipECVDI

HOSPITAL NAME

Mobile Pet Imaging

REFERRING VET

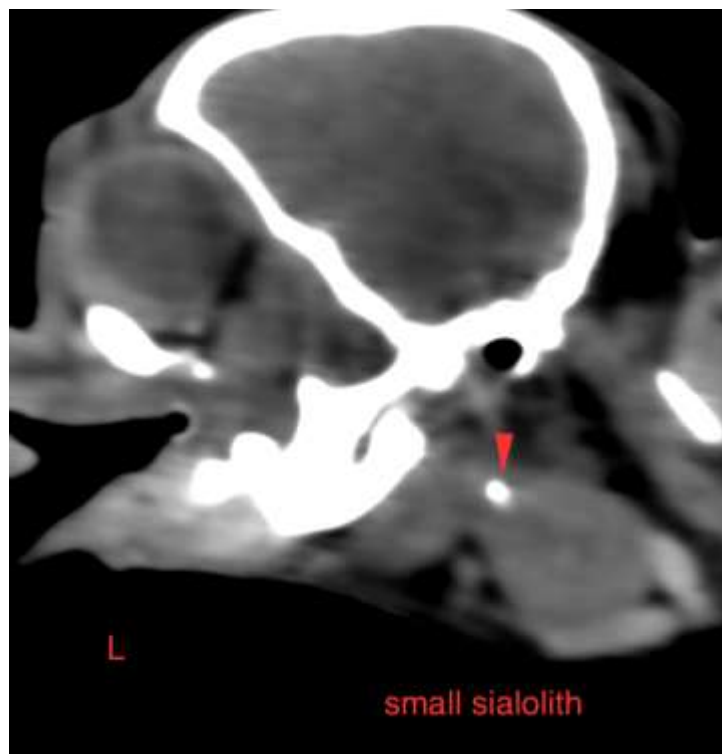
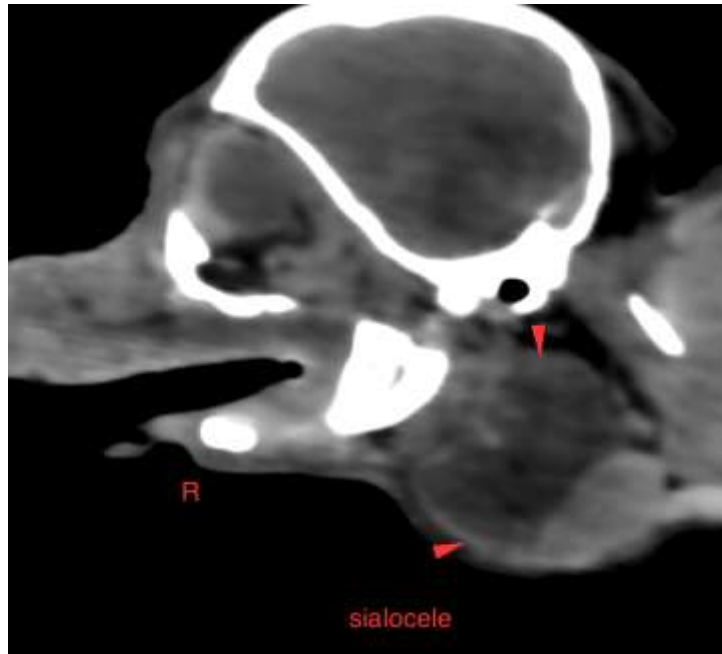Meaux

INVOICE

48749

DATE

12-2-21





PATIENT

Carly Fishman

SPECIES

Canine

BREED

Yorkshire Terrier

SEX

Female Spayed

AGE

12 Years

INTERPRETED BY

Sebastian Schaub, DVM
Dr. med. vet. DipECVDI

HOSPITAL NAME

Mobile Pet Imaging

REFERRING VET

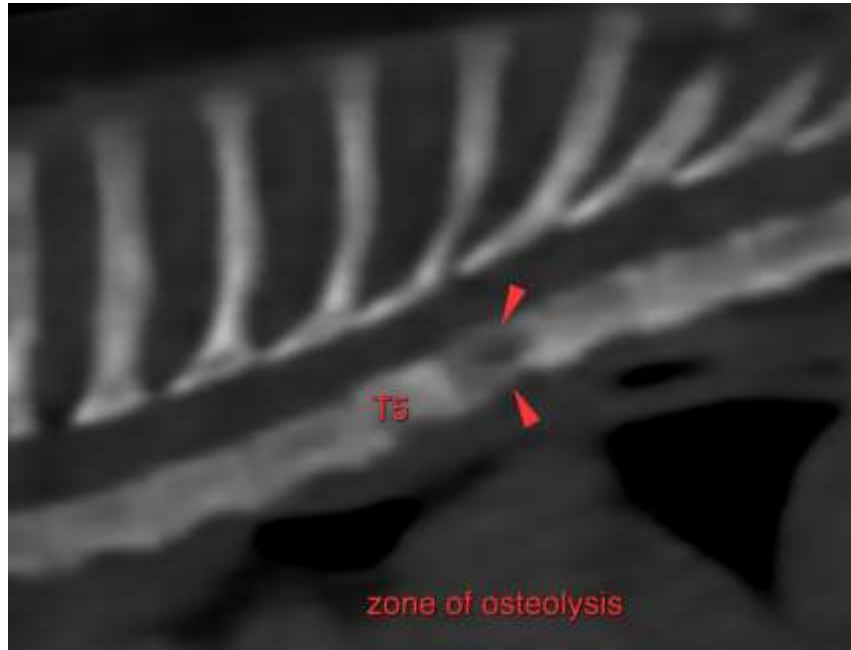
Meaux

INVOICE

48749

DATE

12-2-21



The information and recommendations provided are based on the images presented by the referring veterinarian. No evaluation can be communicated regarding pathology that was not visible in the image/video clips provided.

Thank you for this referral. If the clinical or image interpretation does not parallel your findings or if I can be of any further assistance please contact me.

Sebastian Schaub, Sebastian Schaub, DVM, Dr. med. vet. DipECVDI
sebast.schaub@gmail.com