



PATIENT

Oliver Roman Avila

PRESENTING CLINICAL SIGNS

3 days with anorexia and vomiting. X-rays were taken with Oliver sedated.

SPECIES

Feline

RADIOGRAPHIC STUDY OF THE ABDOMEN

Radiographs of the abdomen in three imaging planes are provided for review.

BREED

Domestic Shorthair

RADIOGRAPHIC FINDINGS

The surrounding bony structures are within normal limits.

No abnormalities of the extraabdominal soft tissues are noted. The abdominal wall is smooth and thin.

SEX

Neutered Male

The serosal detail is maintained throughout the peritoneal and retroperitoneal space.

The liver is appropriate in position, size and presents uniform opacity.

The splenic head is in the anticipated position and within normal limits for size and opacity.

Both kidneys are seen and present with normal size, shape, delineation and opacity. The urinary bladder is in its anticipated position. No radiopaque calculi are noted throughout the upper and lower urinary tract.

AGE

9 Years

The stomach is in its anticipated position and is mildly distended by gas.

INTERPRETED BY

Sebastian Schaub, DVM
Dr. med. vet. DipECVDI

The small intestinal loops are of even diameter and non-dilated, a small amount of gas is seen within the small intestinal loops and considered within normal limits.

The colon is seen in the expected position and is empty, but a small amount of gas.

RADIOGRAPHIC DIAGNOSIS

- Empty gastrointestinal tract with generalized mild gas pattern

HOSPITAL NAME

Alejandrino Animal
Hospital

INTERPRETATION OF THE FINDINGS & FURTHER RECOMMENDATIONS

The radiographic study of the abdomen reveals no abnormalities, explaining the presenting clinical signs. There is no evidence of radiopaque foreign material or signs for gastrointestinal mechanical obstruction. If not done so yet, recommend complete blood work including fpl to screen for underlying pancreatitis or other disease.

REFERRING VET

Dra Alexis Imholz

Check the thorax as there is evidence of mild pleural effusion – possibly secondary to pancreatitis, cardiac disease, hepatic disease, inflammatory, other.

INVOICE

55696

DATE

12-19-22



PATIENT

Oliver Roman Avila

SPECIES

Feline

BREED

Domestic Shorthair

SEX

Neutered Male

AGE

9 Years

INTERPRETED BY

Sebastian Schaub, DVM
Dr. med. vet. DipECVDI

HOSPITAL NAME

Alejandrino Animal
Hospital

REFERRING VET

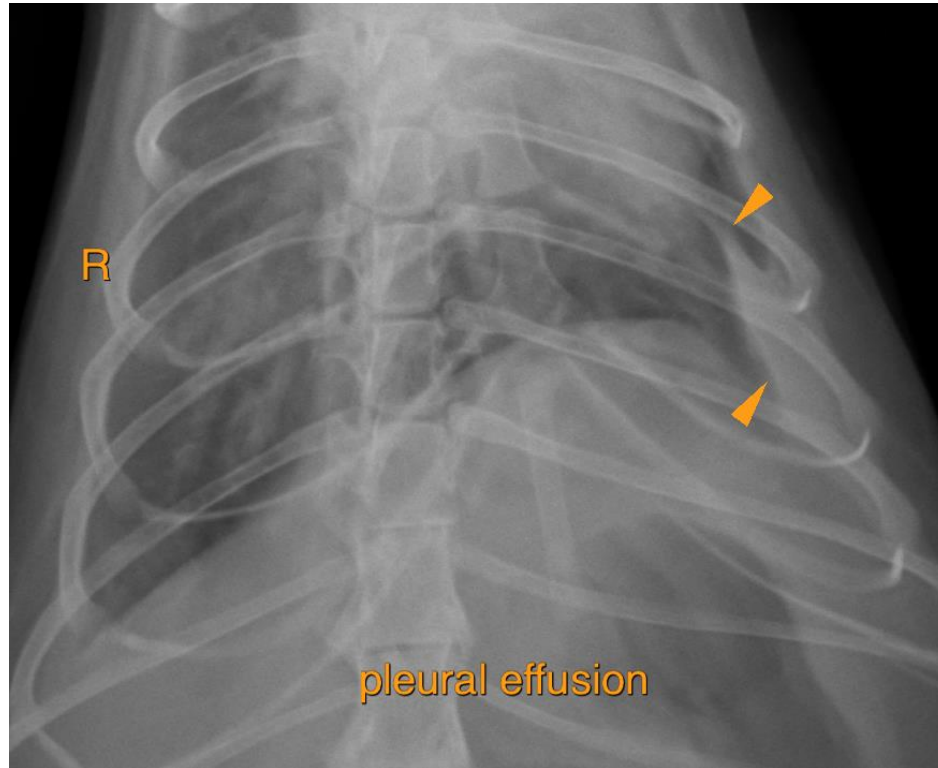
Dra Alexis Imholz

INVOICE

55696

DATE

12-19-22



The information and recommendations provided are based on the images presented by the referring veterinarian/sonographer. No evaluation can be communicated regarding pathology that was not visible in the image/video clips provided.

Thank you for this referral. If the clinical or image interpretation does not parallel your findings or if I can be of any further assistance please contact me.

Sebastian Schaub, Sebastian Schaub, DVM, Dr. med. vet. DipECVDI
sebast.schaub@gmail.com