



**PATIENT**

Montana Toscano

**PRESENTING CLINICAL SIGNS**

Mammary gland tumor for two years has gotten larger. Metastasis check.

**SPECIES**

Canine

**RADIOGRAPHIC STUDY OF THE THORAX**

Radiographs of the thorax in three imaging planes are provided for review.

**BREED**

English Setter

**RADIOGRAPHIC FINDINGS**

The surrounding bony structures are within normal limits.

The nipples are irregularly enlarged and superimposed on the ventral aspect of the thorax in the lateral projections. A mineralizing mammary mass is appreciated at the cranioventral abdominal wall.

**SEX**

Female (not spayed)

The heart is of normal size and shape, there is no evidence of cardiac chamber or vascular enlargement. The pulmonary vasculature is within normal limits.

The cranial mediastinum presents the expected soft tissue opacity. The mediastinal width is less than twice the width of the vertebral column at the same level.

**AGE**

10 Years

The trachea is normal in diameter and presents the anticipated course. The luminal outline of the trachea is smooth.

The bronchial tree presents with thin walls and tapers uniformly towards the periphery as expected.

**INTERPRETED BY**

Sebastian Schaub, DVM  
Dr. med. vet. DipECVDI

The lung parenchyma presents the expected architecture and opacity; the intrapulmonary vascular branching is seen up to the third order lung vessels.

The diaphragm is well delineated with even surface and the expected mild cranial bulging of the diaphragmatic cupola.

**HOSPITAL NAME**

Four Corners  
Veterinary Practice

**RADIOGRAPHIC DIAGNOSIS**

- History of mammary gland tumor with intratumor metaplasia
- Prominent nipples

**REFERRING VET**

Melina Maritato

**INTERPRETATION OF THE FINDINGS & FURTHER RECOMMENDATIONS**

The radiographic study is negative for pulmonary metastatic disease. The nodular opacity superimposed on the costochondral junction of the 8<sup>th</sup> rib pair is suggestive for a superimposed prominent nipple – a small amount of barium can be applied to the nipples on the patient and the lateral radiographs repeated to rule out costal nodule entirely.

**INVOICE**

55690

**DATE**

12-19-22



**PATIENT**

Montana Toscano

**SPECIES**

Canine

**BREED**

English Setter

**SEX**

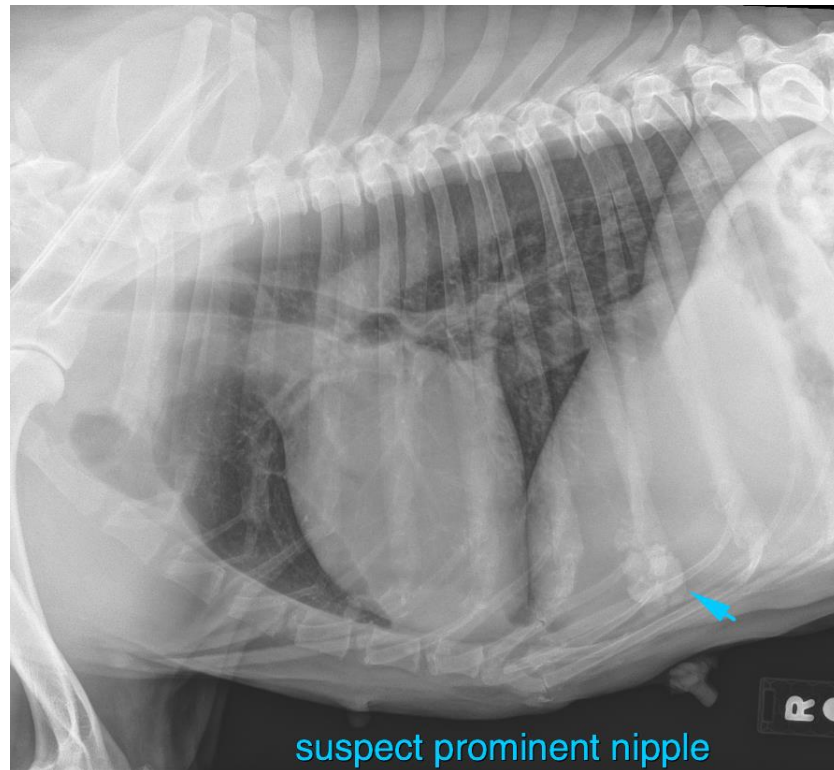
Female (not spayed)

**AGE**

10 Years

**INTERPRETED BY**

Sebastian Schaub, DVM  
Dr. med. vet. DipECVDI



**HOSPITAL NAME**

Four Corners  
Veterinary Practice

**REFERRING VET**

Melina Maritato

**INVOICE**

55690

**DATE**

12-19-22

The information and recommendations provided are based on the images presented by the referring veterinarian/sonographer. No evaluation can be communicated regarding pathology that was not visible in the image/video clips provided.

Thank you for this referral. If the clinical or image interpretation does not parallel your findings or if I can be of any further assistance please contact me.

**Sebastian Schaub**, Sebastian Schaub, DVM, Dr. med. vet. DipECVDI  
sebast.schaub@gmail.com