



**PATIENT**

Felix Lui

**PRESENTING CLINICAL SIGNS**

Ate a ribbon and vomited blood twice but cat is still eating and drinking well. Rule out foreign body.

**SPECIES**

Feline

**RADIOGRAPHIC STUDY OF THE ABDOMEN**

Radiographs of the abdomen in three imaging planes are provided for review.

**BREED**

Domestic Shorthair

**RADIOGRAPHIC FINDINGS**

The surrounding bony structures are within normal limits.

No abnormalities of the extraabdominal soft tissues are noted. The abdominal wall is smooth and thin.

**SEX**

Neutered Male

The serosal detail is maintained throughout the peritoneal and retroperitoneal space.

The liver is appropriate in position, size and presents uniform opacity.

The splenic head is in the anticipated position and within normal limits for size and opacity.

**AGE**

3 Years

Both kidneys are seen and present with normal size, shape, delineation and opacity. The urinary bladder is in its anticipated position. No radiopaque calculi are noted throughout the upper and lower urinary tract.

The stomach is in its anticipated position and presents normal content.

**INTERPRETED BY**

Sebastian Schaub, DVM  
Dr. med. vet. DipECVDI

The small intestinal loops are of even diameter and non-dilated, a small amount of gas is seen within the small intestinal loops and considered within normal limits.

The colon is seen in the expected position and presents with appropriate content.

**HOSPITAL NAME**

Truscott Animal  
Hospital

**RADIOGRAPHIC DIAGNOSIS**

- Normal abdomen

**REFERRING VET**

Dr. Medhat Meawad

**INTERPRETATION OF THE FINDINGS & FURTHER RECOMMENDATIONS**

The radiographic study of the abdomen presents without no evidence of radiopaque foreign material throughout the gastrointestinal tract, nor signs of mechanical obstruction. The material in the stomach is considered as normal chymus. If clinical signs are refractory to therapy and there is suspicion for subileus, recommend follow up radiographs or a complete abdominal ultrasound examination.

**INVOICE**

55699

**DATE**

12-19-22



**PATIENT**

Felix Lui

**SPECIES**

Feline

**BREED**

Domestic Shorthair

**SEX**

Neutered Male

**AGE**

3 Years

**INTERPRETED BY**

Sebastian Schaub, DVM  
Dr. med. vet. DipECVDI

**HOSPITAL NAME**

Truscott Animal  
Hospital

**REFERRING VET**

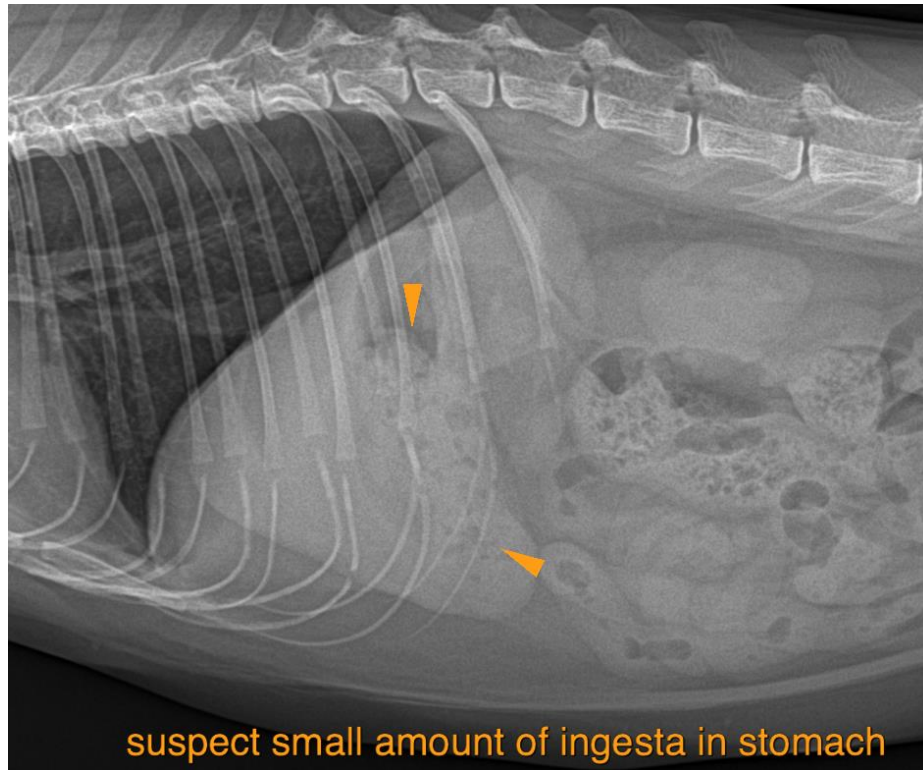
Dr. Medhat Meawad

**INVOICE**

55699

**DATE**

12-19-22



The information and recommendations provided are based on the images presented by the referring veterinarian/sonographer. No evaluation can be communicated regarding pathology that was not visible in the image/video clips provided.

Thank you for this referral. If the clinical or image interpretation does not parallel your findings or if I can be of any further assistance please contact me.

**Sebastian Schaub**, Sebastian Schaub, DVM, Dr. med. vet. DipECVDI  
sebast.schaub@gmail.com