

**PATIENT PRESENTING CLINICAL SIGNS**

Euby Marov Presented for evaluation of 2-year history of weight-bearing lameness of right forelimb per referring DVM. Radiographs revealed suspect flattening of caudal aspect of left humeral head. Both elbow joints showed mild humeral ulnar incongruity with mild degenerative changes.

**SPECIES COMPUTED TOMOGRAPHY OF THE FRONT LIMBS**

Canine A high resolution pre- and post-contrast CT study of the front limbs is provided for review.

**COMPUTED TOMOGRAPHIC FINDINGS**

**BREED** Both shoulder joints present smooth osseous margins and the surrounding soft tissue structures are within normal limits.  
Mixed

**SEX**

FS

The periarticular bones of both elbow joints present very mild osteophyte new bone formation. The tip of the medial coronoid process of the left elbow joint is demarcated by an ill-defined transverse fissure line and the medial coronoid process of the left elbow joint has an irregular shape and heterogeneous density. The medial coronoid process of the right elbow joint presents a generalized heterogeneous density and mild irregular shape.

**COMPUTED TOMOGRAPHIC DIAGNOSIS****AGE**

5 Years

- Coronoid disease elbow joints bilaterally
- Mild degenerative osteoarthritis elbow joints bilaterally
- Normal shoulder joints

**INTERPRETED BY**

Sebastian Schaub, DVM  
Dr. med. vet. DipECVDI

**INTERPRETATION OF THE FINDINGS & FURTHER RECOMMENDATIONS**

The CT study is consistent with coronoid disease of both elbow joints and secondary very mild degenerative osteoarthritis. Arthroscopy to revise the elbow joints is beneficial. The findings of the elbow joints are a plausible source for the presenting clinical signs.

**HOSPITAL NAME**

Mobile Pet Imaging

**REFERRING VET**

Seraydar

**INVOICE**

55694

**DATE**

12-19-22



**PATIENT**

Euby Marov

**SPECIES**

Canine

**BREED**

Mixed

**SEX**

FS

**AGE**

5 Years

**INTERPRETED BY**

Sebastian Schaub, DVM  
Dr. med. vet. DipECVDI

**HOSPITAL NAME**

Mobile Pet Imaging

**REFERRING VET**

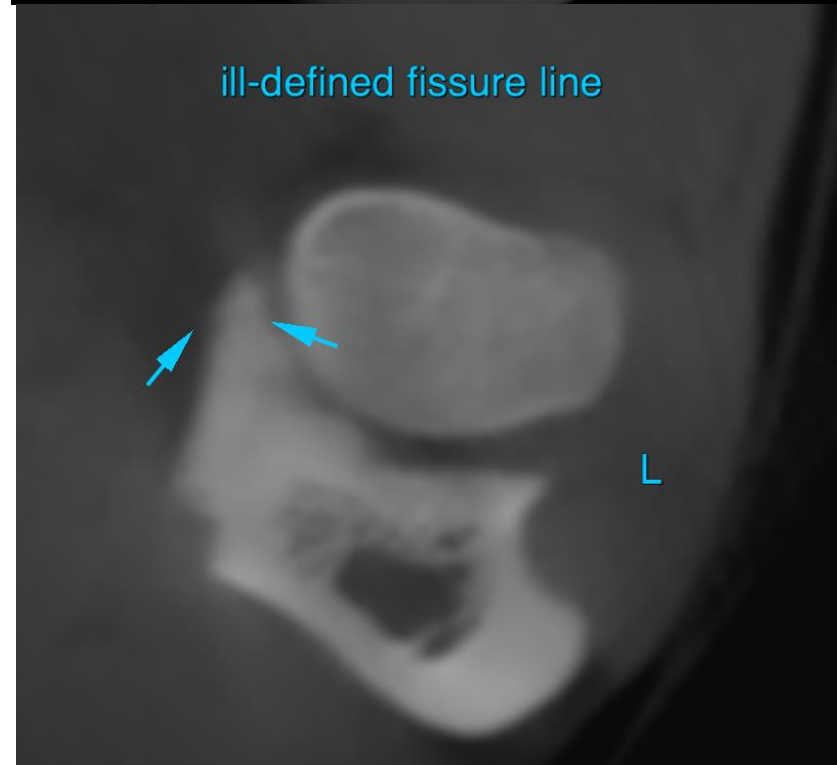
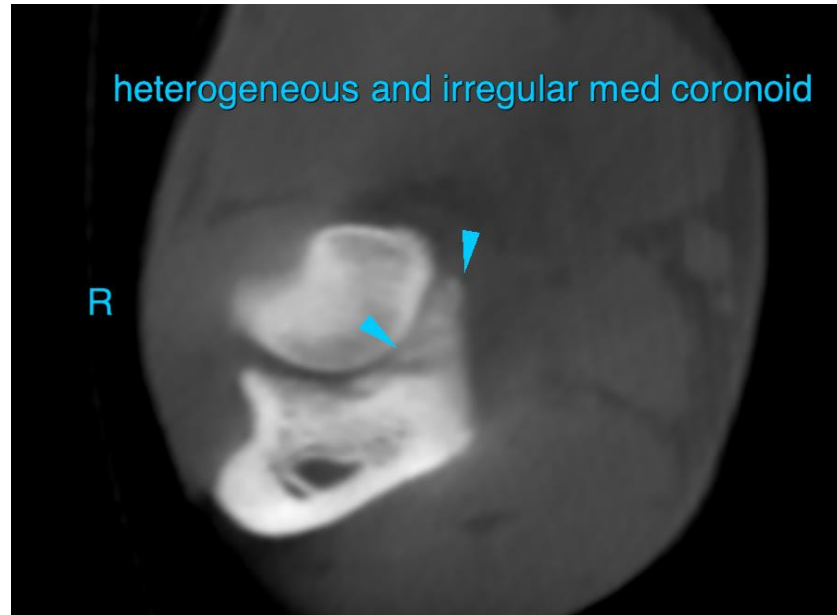
Seraydar

**INVOICE**

55694

**DATE**

12-19-22





**PATIENT**

Euby Marov

The information and recommendations provided are based on the images presented by the referring veterinarian/sonographer. No evaluation can be communicated regarding pathology that was not visible in the image/video clips provided.

**SPECIES**

Canine

Thank you for this referral. If the clinical or image interpretation does not parallel your findings or if I can be of any further assistance please contact me.

**Sebastian Schaub**, Sebastian Schaub, DVM, Dr. med. vet. DipECVDI  
sebast.schaub@gmail.com

**BREED**

Mixed

**SEX**

FS

**AGE**

5 Years

**INTERPRETED BY**

Sebastian Schaub, DVM  
Dr. med. vet. DipECVDI

**HOSPITAL NAME**

Mobile Pet Imaging

**REFERRING VET**

Seraydar

**INVOICE**

55694

**DATE**

12-19-22