



PATIENT

Rex Ma

SPECIES

Canine

BREED

Labrador Retriever

SEX

Male Neutered

AGE

11Y, 2M

WEIGHT

33.2

INTERPRETED BY

Sebastian Schaub, DVM
Dr. med. vet.
DipECVDI

IMAGING PERFORMED BY

Josh

HOSPITAL NAME

CARE Surgery Center

REFERRING VET

Dr. Seth Bleakley

INVOICE

73065

DATE

12-18-25

PRESENTING CLINICAL SIGNS

Soft stool with blood noticed around 12/9/25. Firm mass noted on 12/12 during rectal exam associated with the right anal gland, as well as, along ventral rectal wall. Metcheck/lymph node check

COMPUTED TOMOGRAPHY OF THE THORAX AND ABDOMEN

A high resolution pre- and post-contrast CT study of the abdomen and a plain CT study of the thorax is provided for review.

COMPUTED TOMOGRAPHIC FINDINGS

Thorax

The bony and surrounding soft tissue structures are within normal limits.

The sternal, cranial mediastinal and tracheobronchial lymph nodes are small elongated with a normal short-to-long-axis-ratio is < 0.5, the attenuation pattern is uniform.

The cardiovascular structures including the pulmonary vasculature are within normal limits.

The bronchial tree presents with regular branching and tapers uniformly towards the periphery as expected, the bronchial walls are thin and smooth. The bronchus-to-artery ratio is within normal limits.

The lung parenchyma presents the expected architecture and attenuation behavior with randomly distributed interspersed punctuate mineralization.

Small incidental gas pockets are seen within the esophageal lumen; there is no evidence of abnormal dilation.

Abdomen

The serosal fat presents normal attenuation behavior. There is no evidence of peritoneal effusion or peritonitis.

Both kidneys present within normal limits for size, shape and organ architecture.

The adrenal glands are within normal limits for size, shape and organ architecture.

Both liver and spleen present with normal shape, even surface, uniformly attenuating parenchyma.

The pancreas is evenly contoured; the pancreatic parenchyma is homogeneous.

The position, delineation, wall and content of the gastrointestinal tract are considered within normal limits throughout. In the region of the right anal sac, an irregular ovoid shaped, uniform soft tissue attenuating and mild irregular contrast enhancing mass is seen; measuring 4.4 x 3.4 x 3.9 cm. The rectum/anus are distorted by the mass effect.

The hypogastric lymph nodes are small.

The bony and surrounding soft tissue structures reveal no abnormalities.

COMPUTED TOMOGRAPHIC DIAGNOSIS

- Soft tissue mass region of right anal sac
- Normal thorax, no evidence of pulmonary metastatic disease
- No signs of macroscopic lymph node metastasis



PATIENT

Rex Ma

SPECIES

Canine

BREED

Labrador Retriever

SEX

Male Neutered

AGE

11Y, 2M

WEIGHT

33.2

INTERPRETED BY

Sebastian Schaub, DVM
Dr. med. vet.
DipECVDI

IMAGING PERFORMED BY

Josh

HOSPITAL NAME

CARE Surgery Center

REFERRING VET

Dr. Seth Bleakley

INVOICE

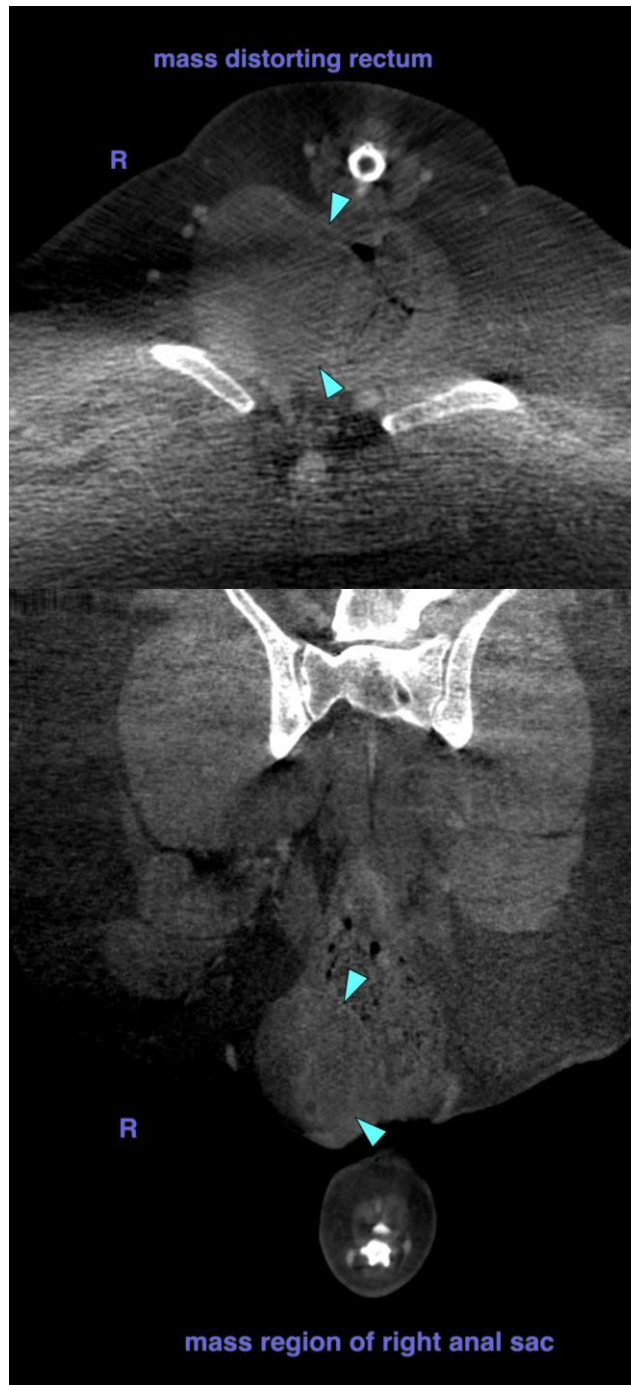
73065

DATE

12-18-25

INTERPRETATION OF THE FINDINGS & FURTHER RECOMMENDATIONS

The odds for primary soft tissue neoplasm of the right anal sac are high – anal sac adenocarcinoma is most common. The mass of the right anal sac is distorting the rectum at the same level, there is uncertainty if there is only mass effect on the rectal wall (prioritized) or infiltrative growth.





PATIENT

Rex Ma

SPECIES

Canine

BREED

Labrador Retriever

SEX

Male Neutered

AGE

11Y, 2M

WEIGHT

33.2

INTERPRETED BY

Sebastian Schaub, DVM
Dr. med. vet.
DipECVDI

**IMAGING
PERFORMED BY**

Josh

HOSPITAL NAME

CARE Surgery Center

REFERRING VET

Dr. Seth Bleakley

INVOICE

73065

DATE

12-18-25

The information and recommendations provided are based on the images presented by the referring veterinarian/sonographer. No evaluation can be communicated regarding pathology that was not visible in the image/video clips provided.

Thank you for this referral. If the clinical or image interpretation does not parallel your findings or if I can be of any further assistance please contact me.

Sebastian Schaub, Sebastian Schaub, DVM, Dr. med. vet. DipECVDI
info@sonopath.com