

**PATIENT**

Baraka Winters

PRESENTING CLINICAL SIGNS

Baraka has Chronic Kidney Disease. On recent screening bloodwork, her ALT was elevated. Looking for causes of liver stress.
Abnormal PE/Chem/CBC/UA Results: BUN 41, Creatinine 2.8, ALT 167. All other values normal.

SPECIES

Feline

COMPUTED TOMOGRAPHY OF THE ABDOMEN

A high resolution plain CT study of the abdomen is provided for review.

BREED

Domestic Shorthair

COMPUTED TOMOGRAPHIC FINDINGS

The serosal fat presents normal attenuation behavior. There is no evidence of peritoneal effusion or peritonitis.

SEX

FS

Both kidneys present within normal limits for size, shape and organ architecture.

The adrenal glands are within normal limits for size, shape and organ architecture.

AGE

16 Years

Both liver and spleen present with normal shape, even surface, uniformly attenuating parenchyma.

The pancreas is evenly contoured, the pancreatic parenchyma is homogeneous.

INTERPRETED BY

Sebastian Schaub, DVM
Dr. med. vet. DipECVDI

The position, delineation, wall and content of the gastrointestinal tract are considered within normal limits throughout.

The intervertebral disc space L6/L7 is moderately narrowed

HOSPITAL NAME

Animal Health Care
Denver

COMPUTED TOMOGRAPHIC DIAGNOSIS

- Discopathy L6/L7 without evidence of compressive myelopathy
- Otherwise normal abdomen

REFERRING VET

Cathryn Sayer

INTERPRETATION OF THE FINDINGS & FURTHER RECOMMENDATIONS

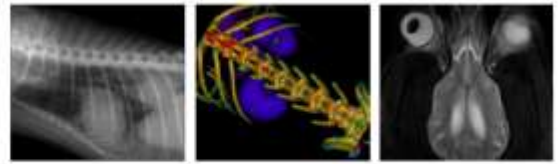
The CT study of the abdomen presents without clinically relevant abnormalities. Please be aware, that evaluation of the architecture of the parenchymal organs is limited in a plain CT study.

INVOICE

49131

DATE

12-18-21



PATIENT

Baraka Winters

The information and recommendations provided are based on the images presented by the referring veterinarian. No evaluation can be communicated regarding pathology that was not visible in the image/video clips provided.

Thank you for this referral. If the clinical or image interpretation does not parallel your findings or if I can be of any further assistance please contact me.

SPECIES

Feline

Sebastian Schaub, Sebastian Schaub, DVM, Dr. med. vet. DipECVDI
sebast.schaub@gmail.com

BREED

Domestic Shorthair

SEX

FS

AGE

16 Years

INTERPRETED BY

Sebastian Schaub, DVM
Dr. med. vet. DipECVDI

HOSPITAL NAME

Animal Health Care
Denver

REFERRING VET

Cathryn Sayer

INVOICE

49131

DATE

12-18-21