



PATIENT

Poppy Lockett

SPECIES

Feline

BREED

DSH

SEX

MN

AGE

10

WEIGHT

11.9

INTERPRETED BY

Sebastian Schaub, DVM
Dr. med. vet.
DipECVDI

IMAGING PERFORMED BY

Carissa

HOSPITAL NAME

Scottsdale Veterinary
Clinic

REFERRING VET

Dr. Hawken

INVOICE

73040

DATE

12-17-25

PRESENTING CLINICAL SIGNS

Cranial mediastinal mass

COMPUTED TOMOGRAPHY OF THE THORAX

A high resolution pre- and post-contrast CT study of the thorax is provided for review.

COMPUTED TOMOGRAPHIC FINDINGS

The bony and surrounding soft tissue structures are within normal limits.

In the cranioventral aspect of the mediastinum, cranial to the heart, a well-defined, uniform soft tissue attenuating and moderate contrast enhancing roundish mass is seen; measuring 2.9 x 1.9 x 5.3 cm.

The cardiovascular structures including the pulmonary vasculature are within normal limits.

The bronchial tree presents with regular branching and tapers uniformly towards the periphery as expected, the bronchial walls are thin and smooth. The bronchus-to-artery ratio is within normal limits.

The lung parenchyma presents the expected architecture and attenuation behavior, but zones with dystelectasis – accentuated level with the heart.

Small incidental gas pockets are seen within the esophageal lumen; there is no evidence of abnormal dilation.

COMPUTED TOMOGRAPHIC DIAGNOSIS

- Cranioventral mediastinal soft tissue mass without vascular invasion

INTERPRETATION OF THE FINDINGS & FURTHER RECOMMENDATIONS

The cranioventral mediastinal soft tissue mass can present an enlarged cranial mediastinal lymph node (e.g. lymphoma) or is of thymic origin (e.g. thymoma, thymic sarcoma/carcinoma/lymphosarcoma). Ectopic thyroid carcinoma is a less likely differential. Ultrasound guided FNS sampling can be performed for specification. Depending on results of the advanced diagnostic test, surgical excision may be a feasible treatment option.



PATIENT

Poppy Lockett

SPECIES

Feline

BREED

DSH

SEX

MN

AGE

10

WEIGHT

11.9

INTERPRETED BY

Sebastian Schaub, DVM
Dr. med. vet.
DipECVDI

IMAGING PERFORMED BY

Carissa

HOSPITAL NAME

Scottsdale Veterinary
Clinic

REFERRING VET

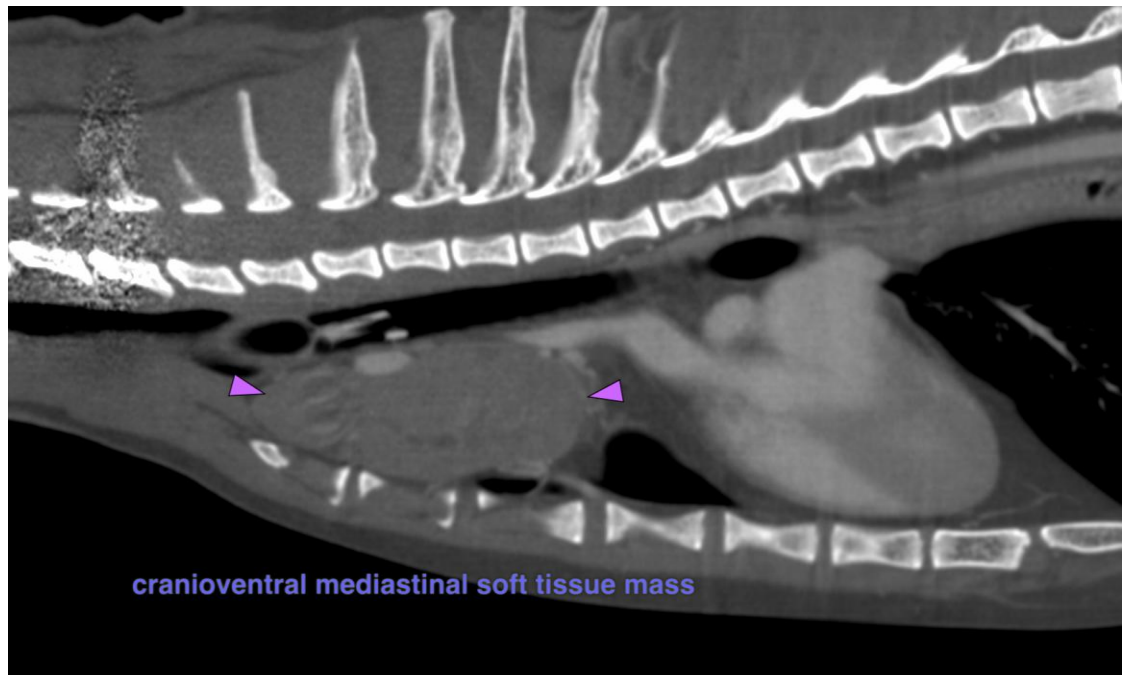
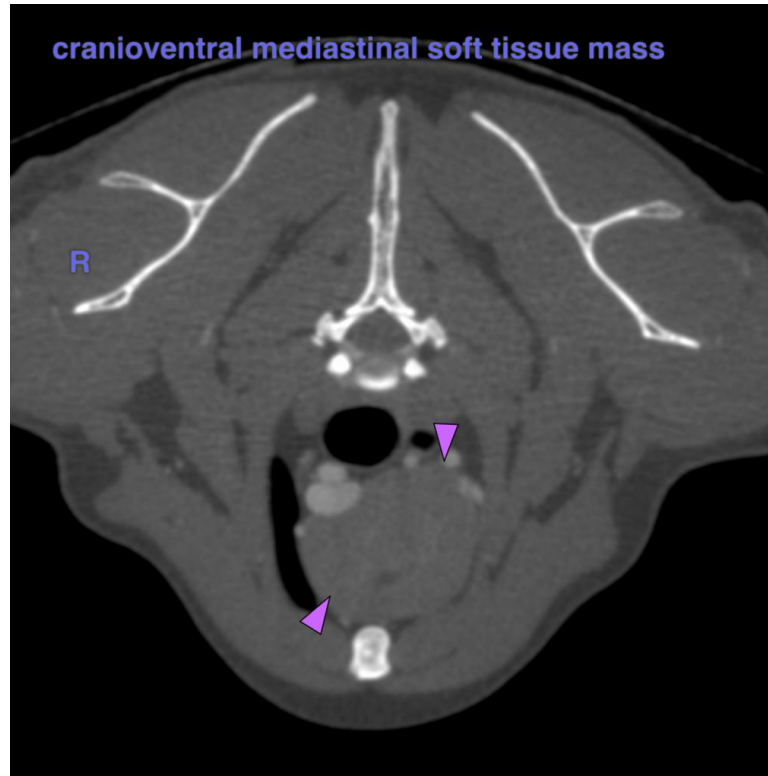
Dr. Hawken

INVOICE

73040

DATE

12-17-25





PATIENT

Poppy Lockett

SPECIES

Feline

BREED

DSH

SEX

MN

AGE

10

WEIGHT

11.9

INTERPRETED BY

Sebastian Schaub, DVM
Dr. med. vet.
DipECVDI

IMAGING PERFORMED BY

Carissa

HOSPITAL NAME

Scottsdale Veterinary
Clinic

REFERRING VET

Dr. Hawken

INVOICE

73040

DATE

12-17-25

The information and recommendations provided are based on the images presented by the referring veterinarian/sonographer. No evaluation can be communicated regarding pathology that was not visible in the image/video clips provided.

Thank you for this referral. If the clinical or image interpretation does not parallel your findings or if I can be of any further assistance please contact me.

Sebastian Schaub, Sebastian Schaub, DVM, Dr. med. vet. DipECVDI
info@sonopath.com